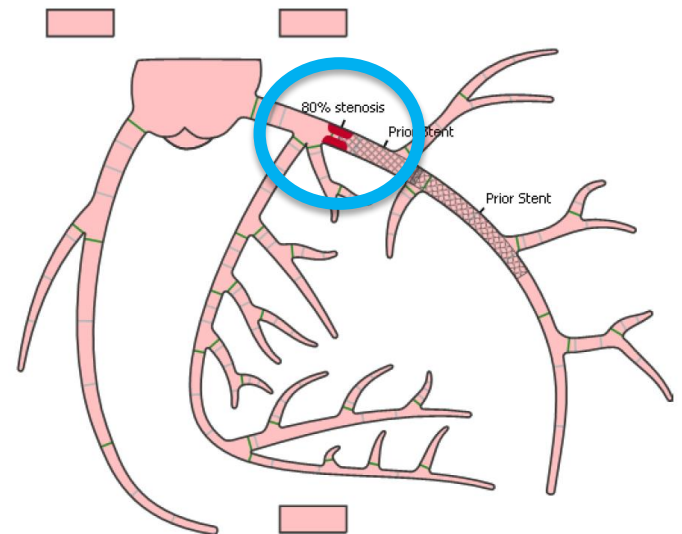
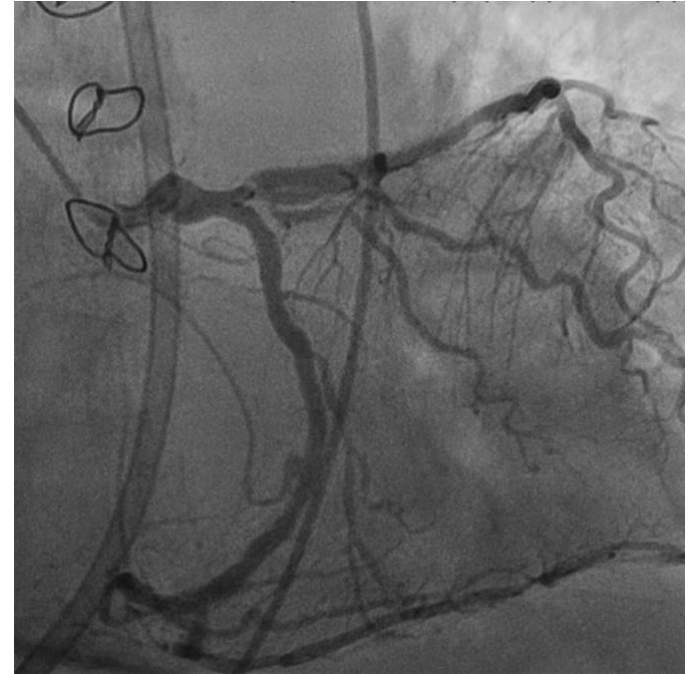

- 63 year old Male
- ESRF, Hep C liver cirrhosis, Anaemia (PUD, Esophageal varices), Thrombocytopaenia
- LVEF 33%
- Aug 17: PCI BMS x 2 p-mLAD
- Dec 17:
 - Type 2 MI
 - CAG: SVD with ostial LAD 80%



Target Lesion: Ostial LAD

PCR