



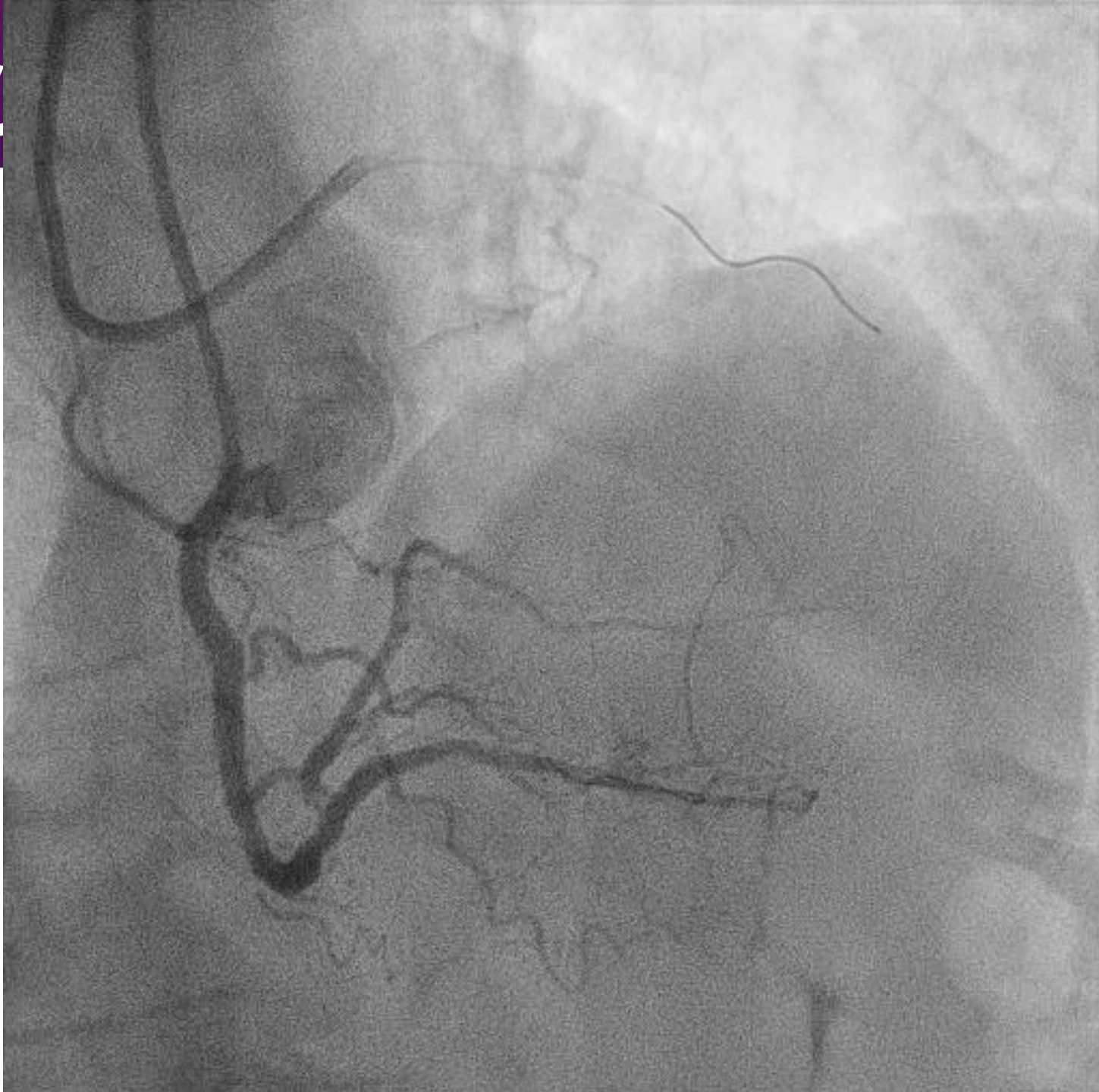
Looking down a double barrel

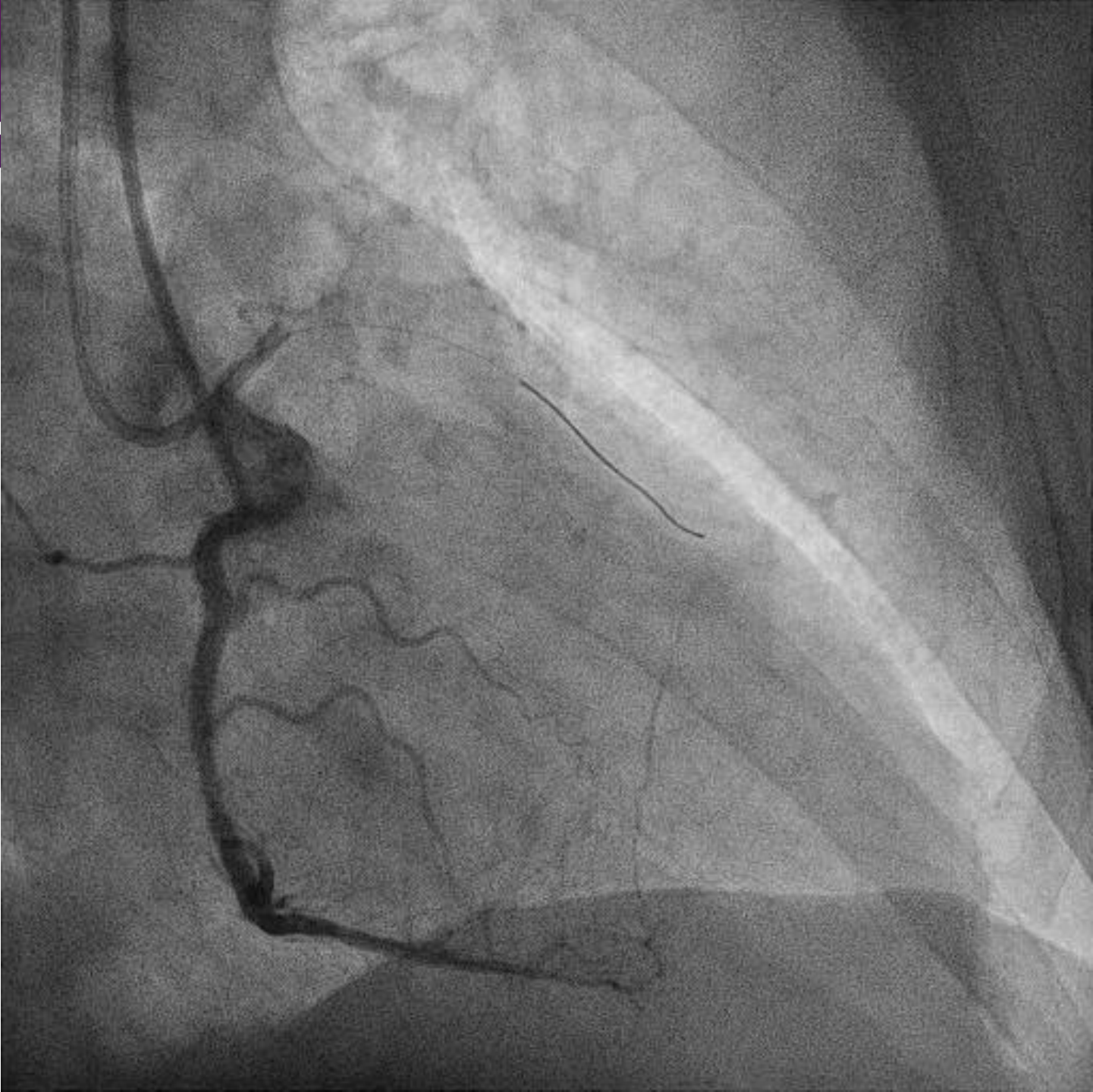
‘V stent’ reconstruction in separate LAD and
circumflex ostia following 3 vessel PCI

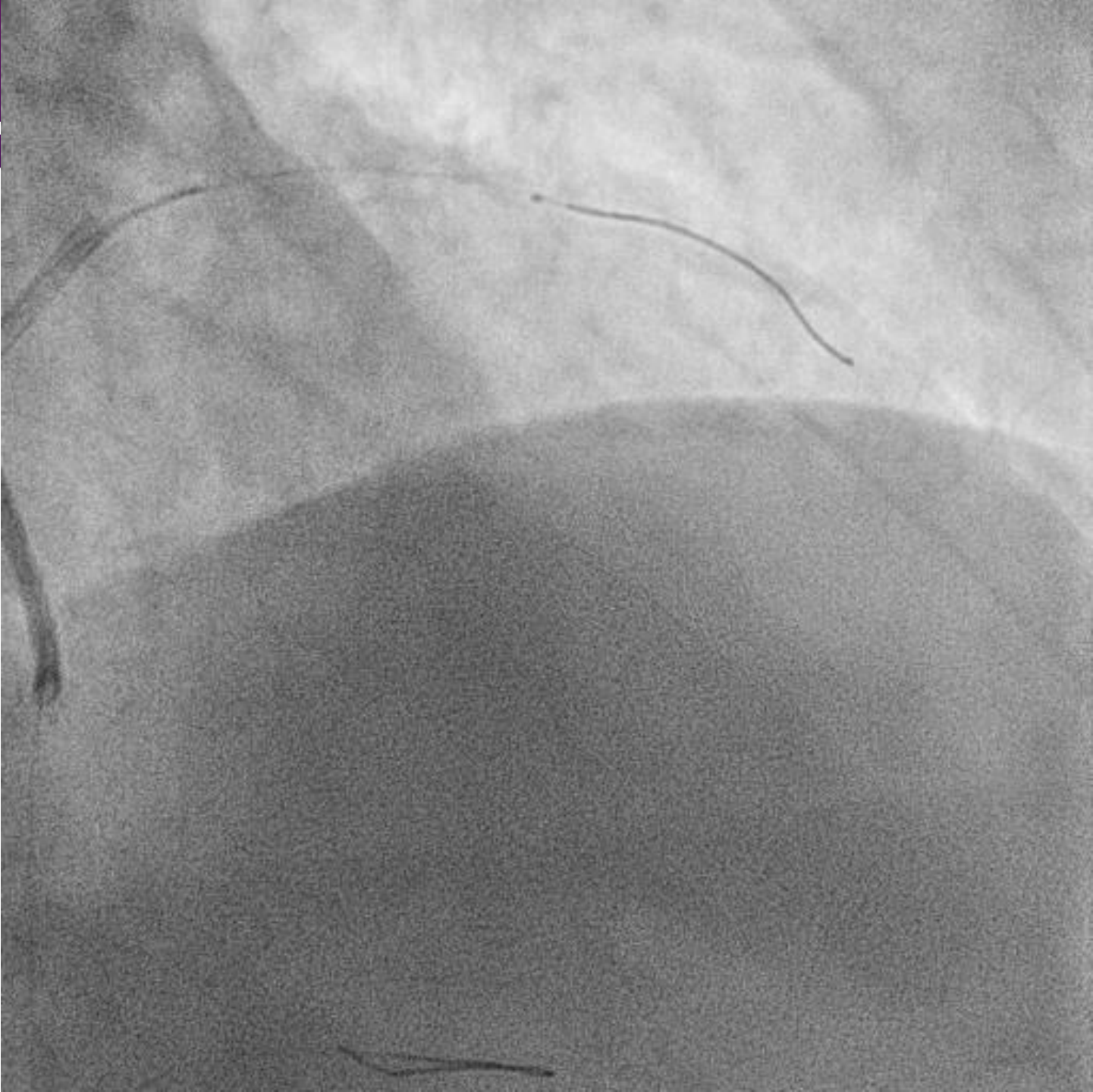Dr Jack Laffan

Royal Victoria Hospital, Belfast

- 72yo man presents with NSTEMI
- Normal LV and renal function
- Asbestosis with impaired lung function. Heart team decision - PCI









94

10.1

RAO 35

CRAN 35

Height
cm +1

SID 121

FD 20

Exp 15

Fluo Low

Time 05:03

K **0.46**
mGy/s



70
min

K	156 mg
---	-----------

14:26

FFR	DFR	IVUS
-----	-----	------

Close Case

Worklist

OptiCross HD

Vessel

Imaging

Manual ☒ Auto

REC


Bookmark

Video Help

CASE SETTINGS

07-12-2020 03:17 PM

Frame 0
Pullback 0.0 mm

