



How to (un)wittingly remove implanted 3,5/33 DES from proximal LAD?

Dariusz Plewik, Poland

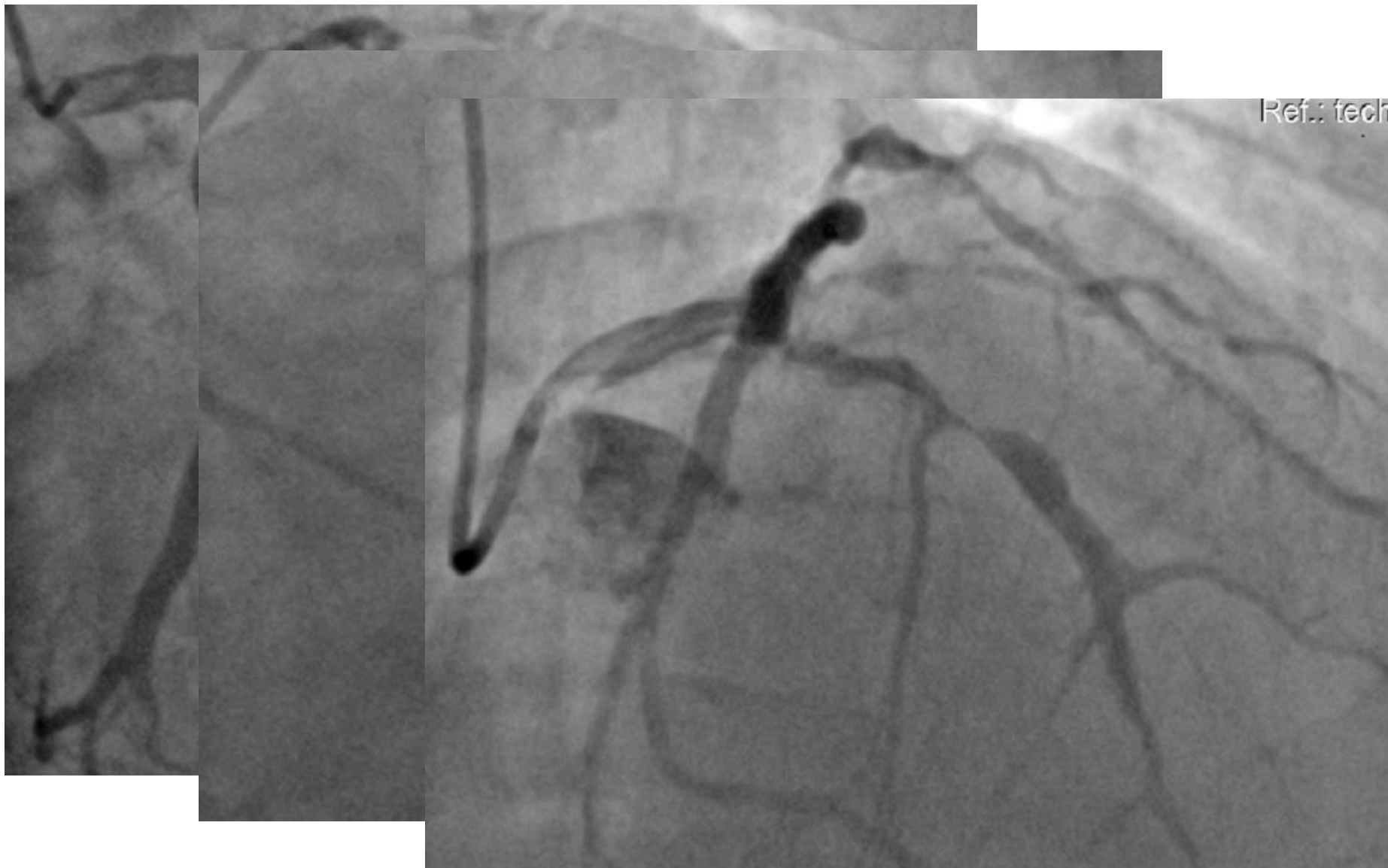
Pope John Paul II Hospital, Zamosc

- 53 year old men
- Hypertensive ,smoker, obese
- Anterior STEMI presentation
- 3 vessel disease with CTO RCA, culprit occlusion of LAD and significant stenosis of Cx/OM
- Immediately primary PCI of LAD
- PCI Cx/OM planned as a second stage of treatment

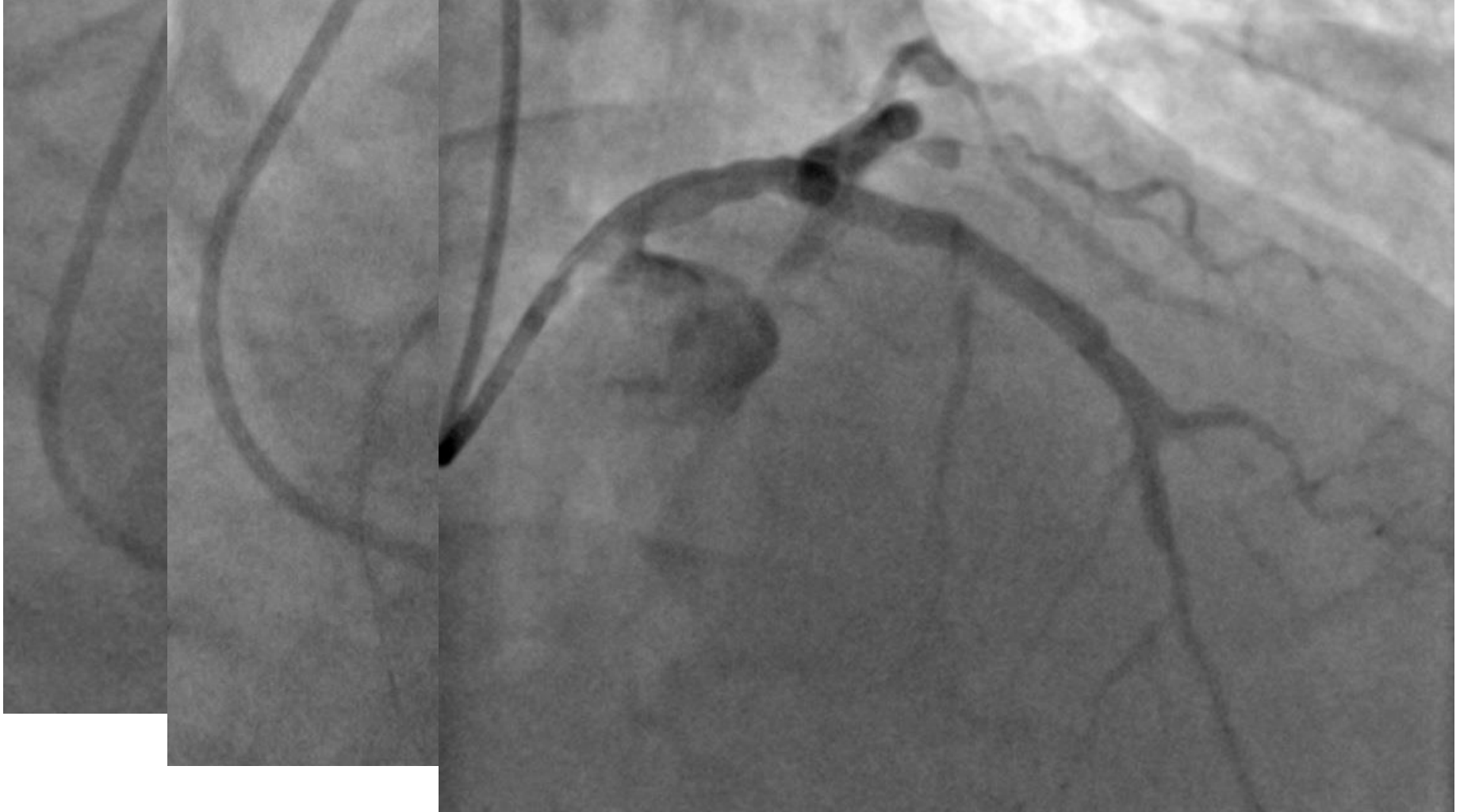
Routine revascularization of non-IRA lesions should be considered in patients with multivessel disease before hospital discharge.²¹¹⁻²¹⁴

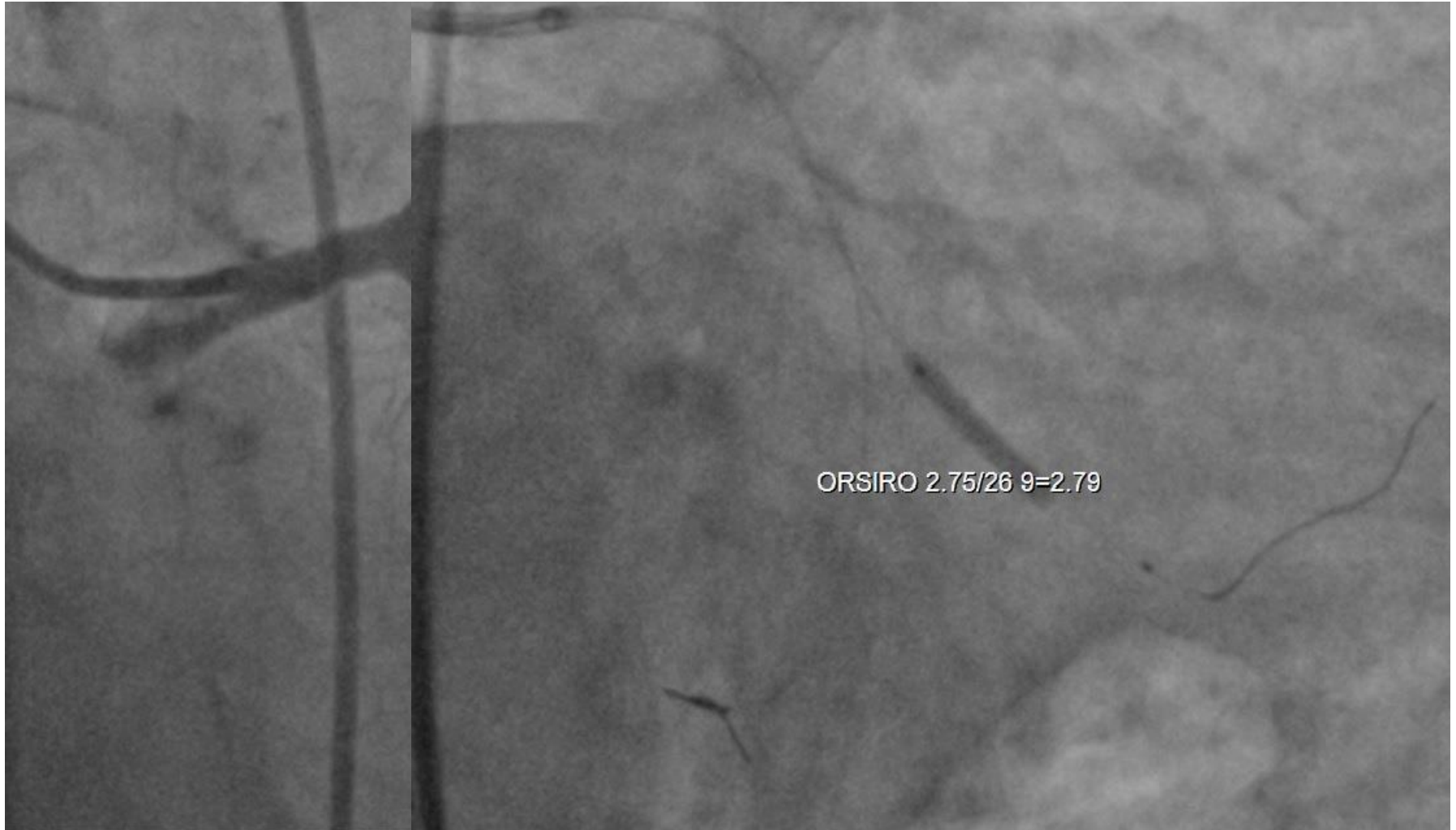IIa

A



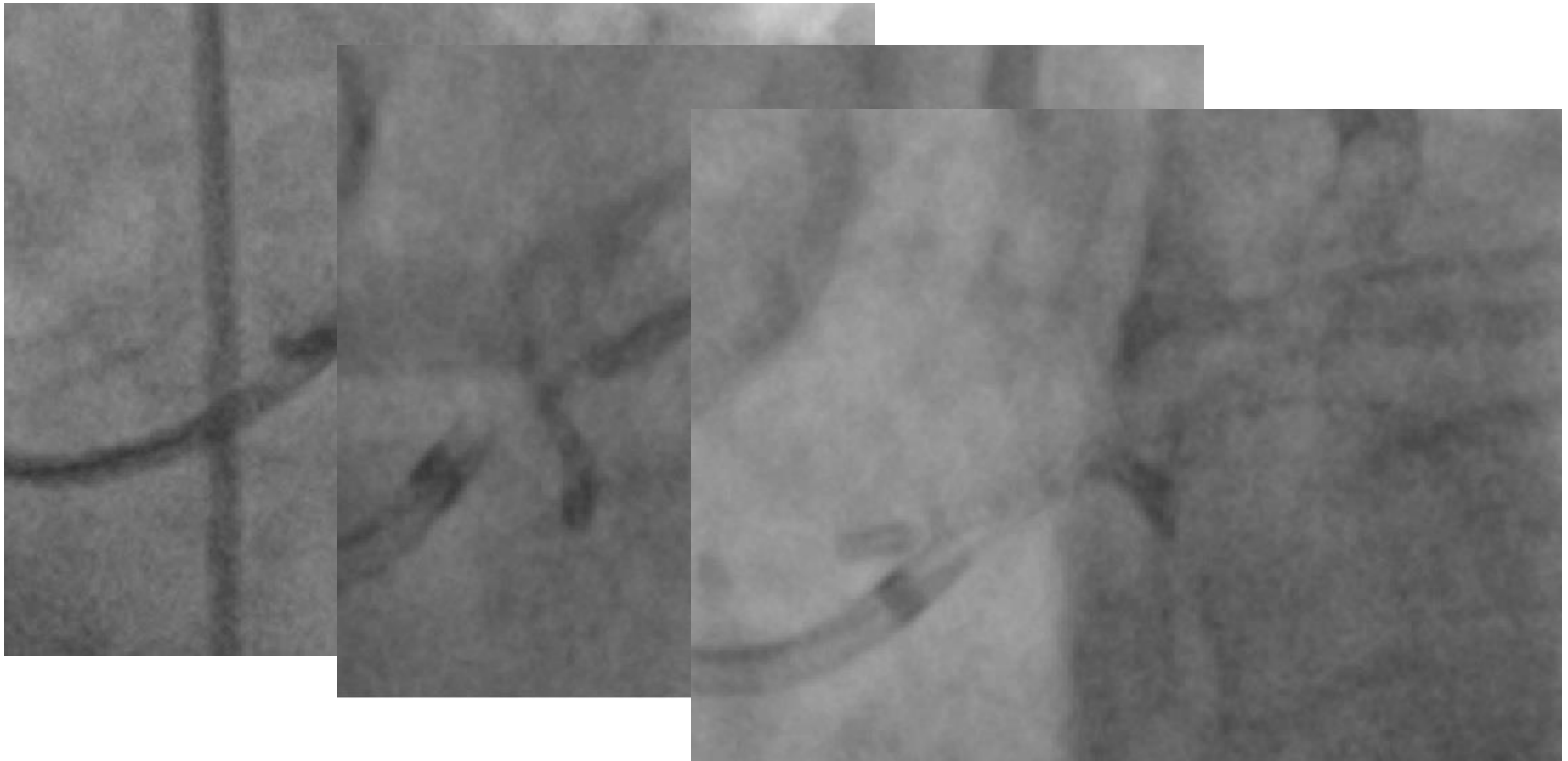
Xience 3,5 33mm, NC balloon 4,0/20mm 22ATM (4,25mm)




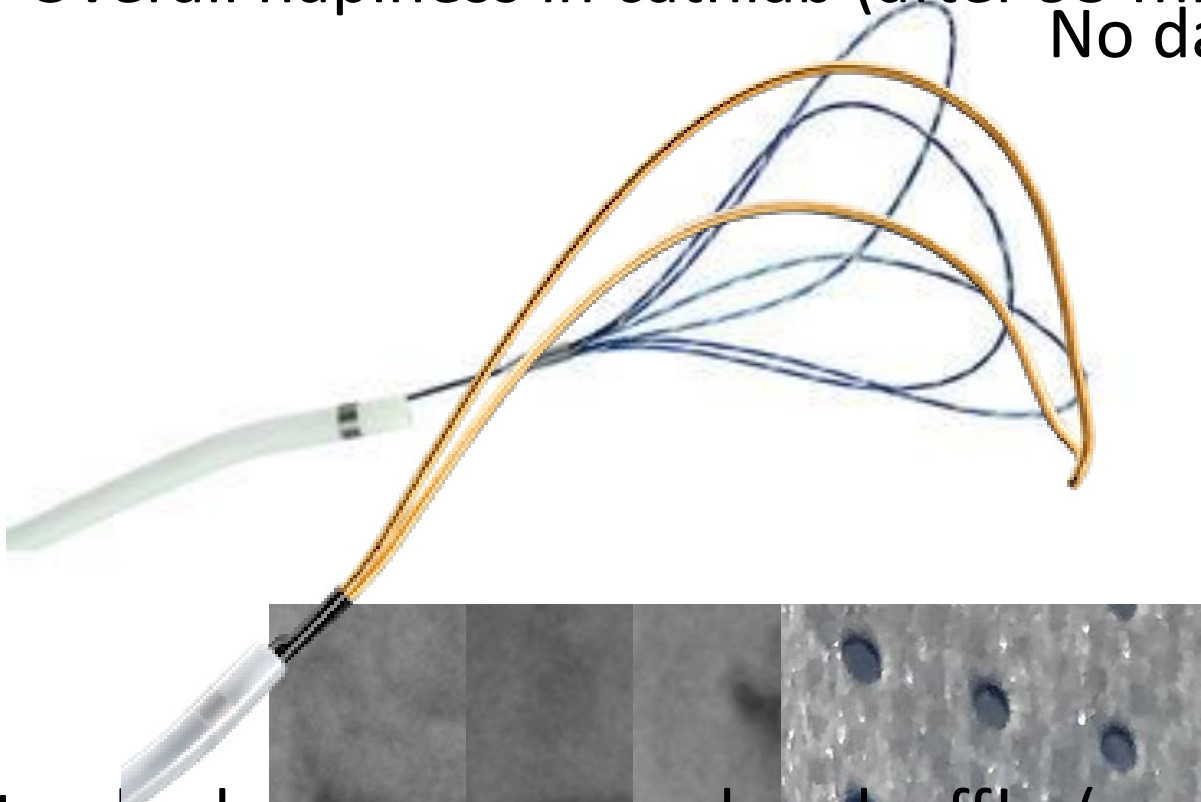


First stenting OM due to discrepancy of diameters OM/Cx

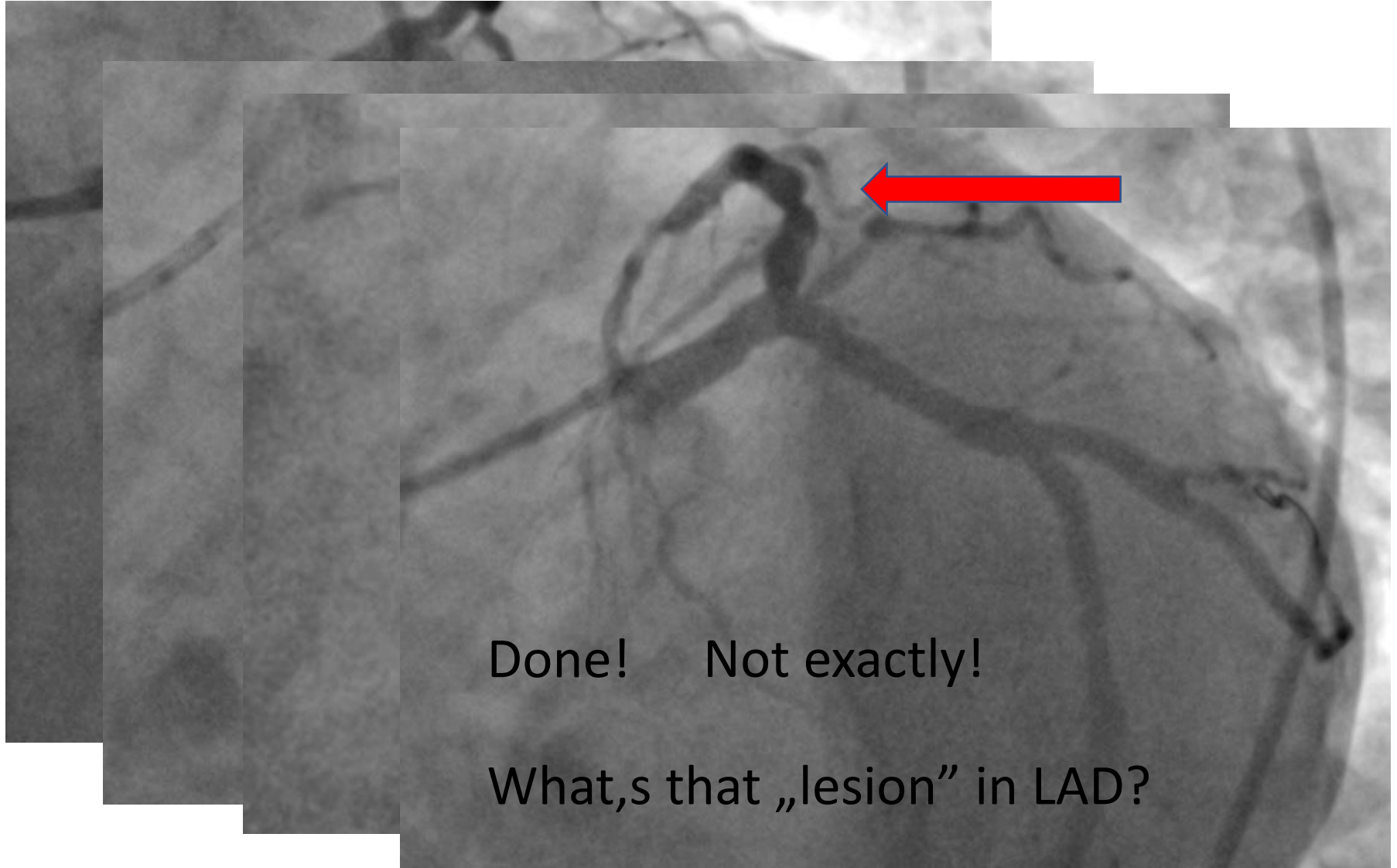
Second stent planned from Cx to OM – stuck in LM/Cx
,drawed back to LM ostium and slipped (Promus 3,5/16mm)



Overall happiness in cathlab (after 95 minutes of work)
No damage in LM :-)

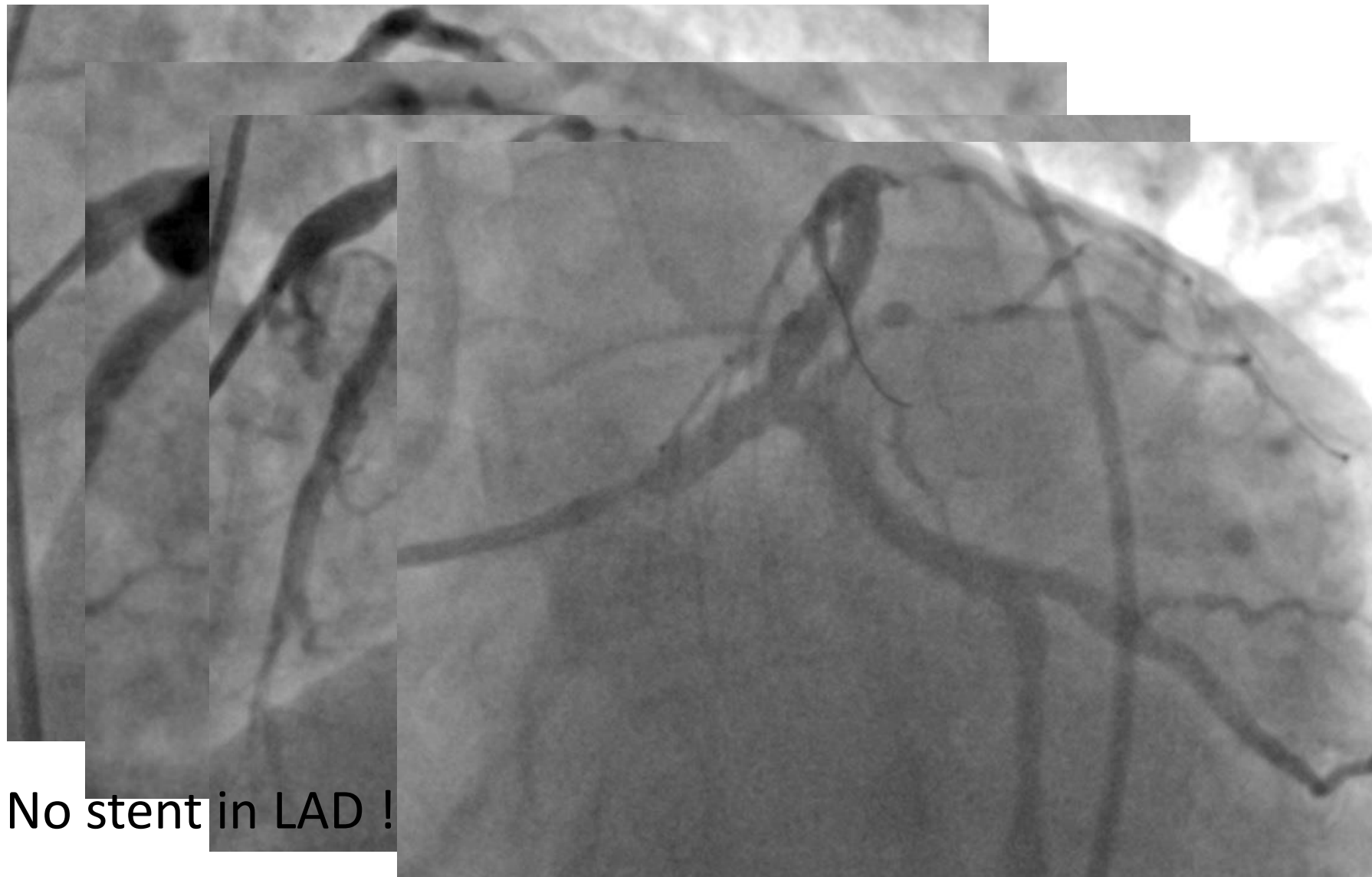


Standard coronary snare break off! :-(
Senior operator: „That was biggest force I had to use in
vessels in my 20-year experience”



Done! Not exactly!

What,s that „lesion” in LAD?



No stent in LAD !

- Minimally protruded first stent to LM? (first procedure)
- Wire through struts of stent (second procedure). Slippery Orsiro goes through ,Promus not
- Retrieve much more than we expect ! (but we missed it at first look)

