

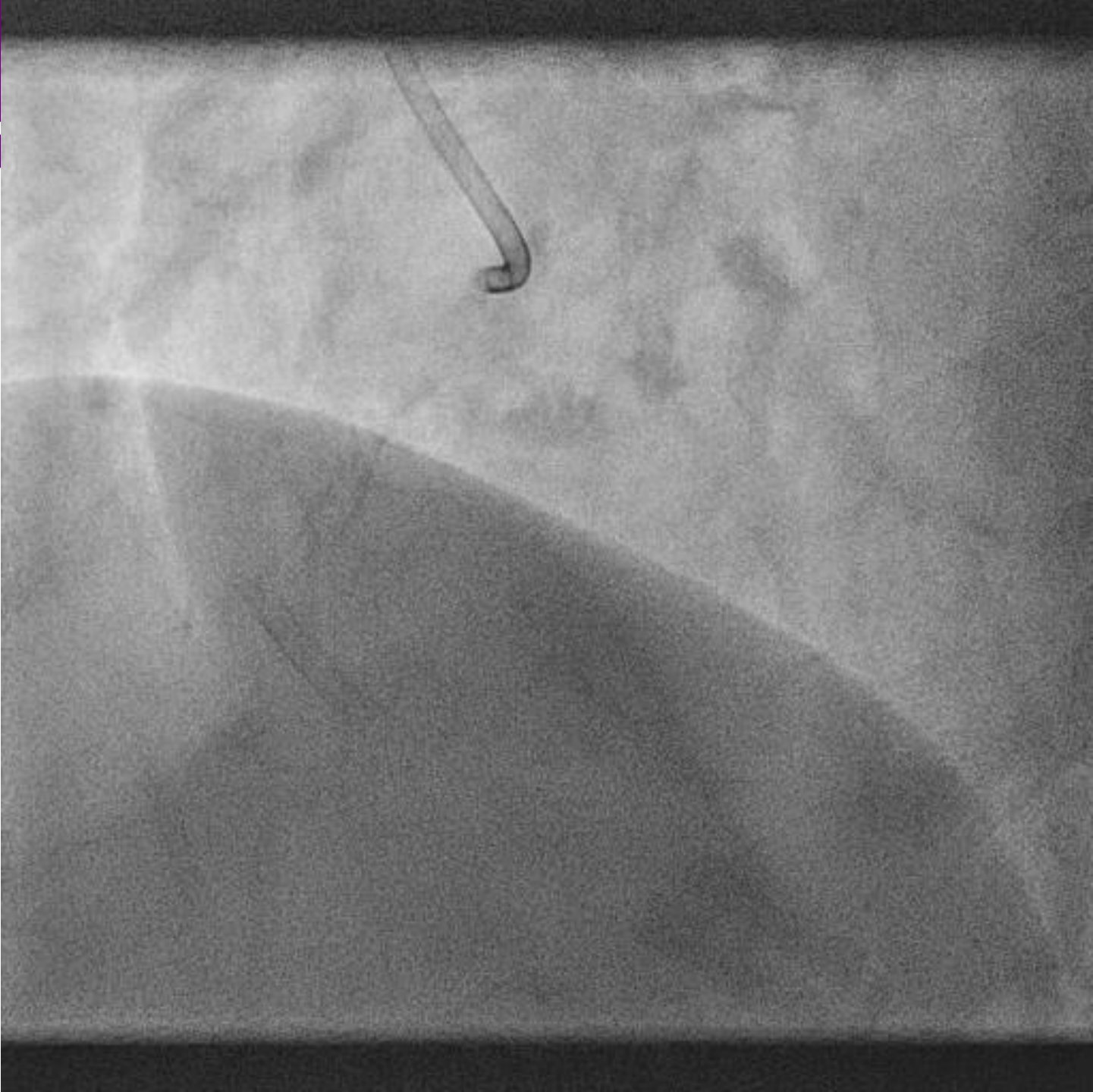


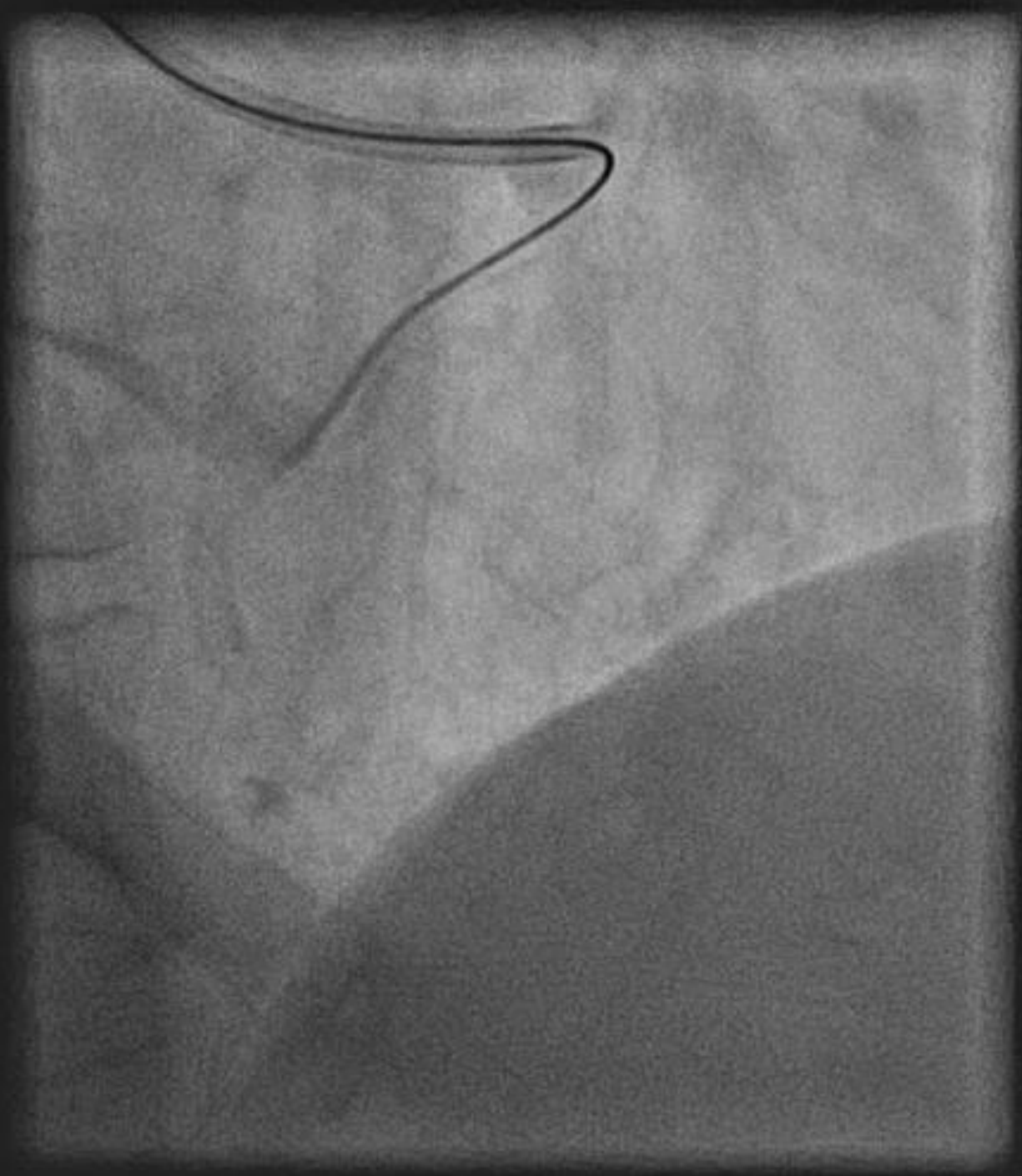
Trying to wire around the bend

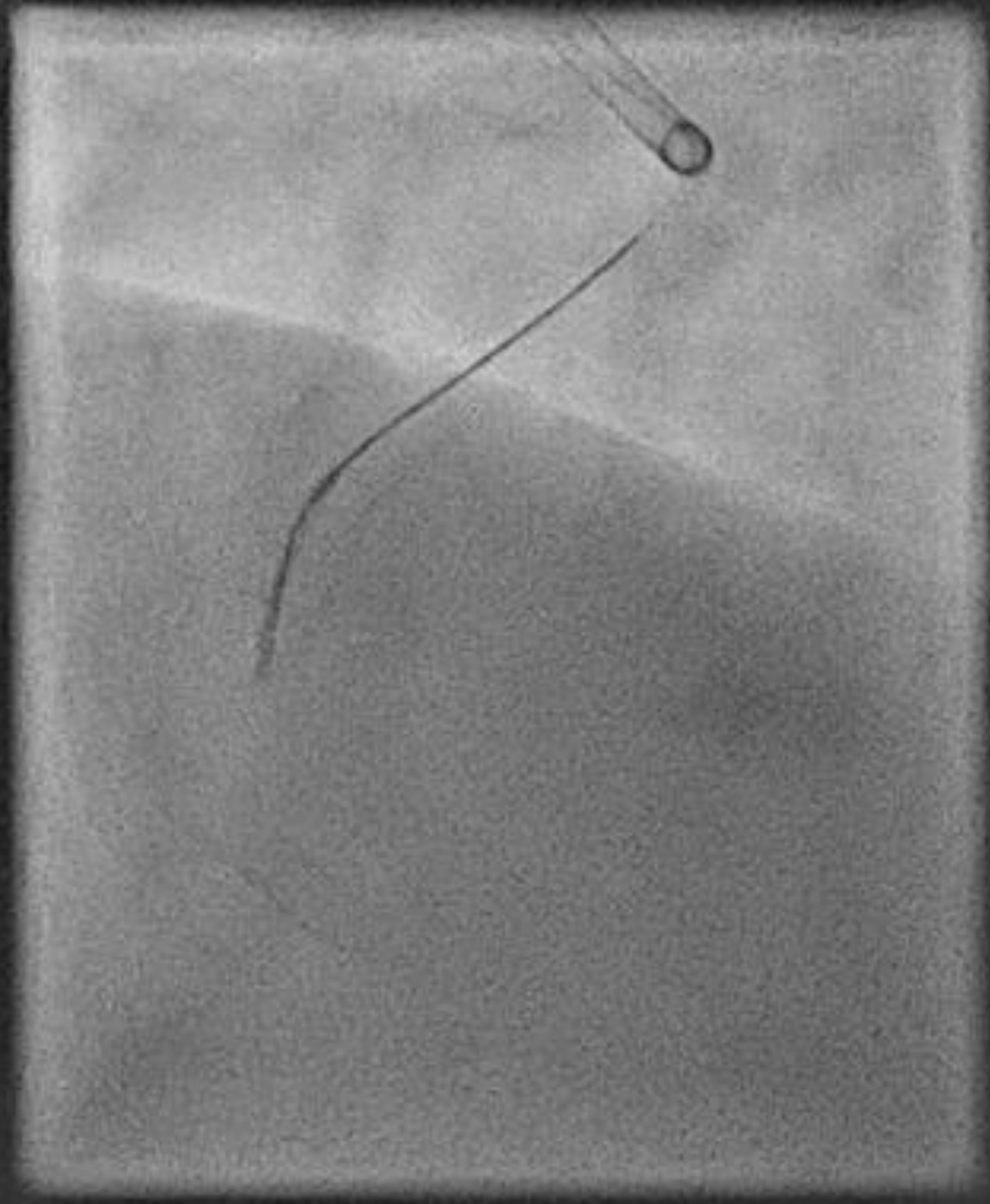
Sub-intimal dissection and stabilisation to facilitate
antegrade wiring of tortuous RCA

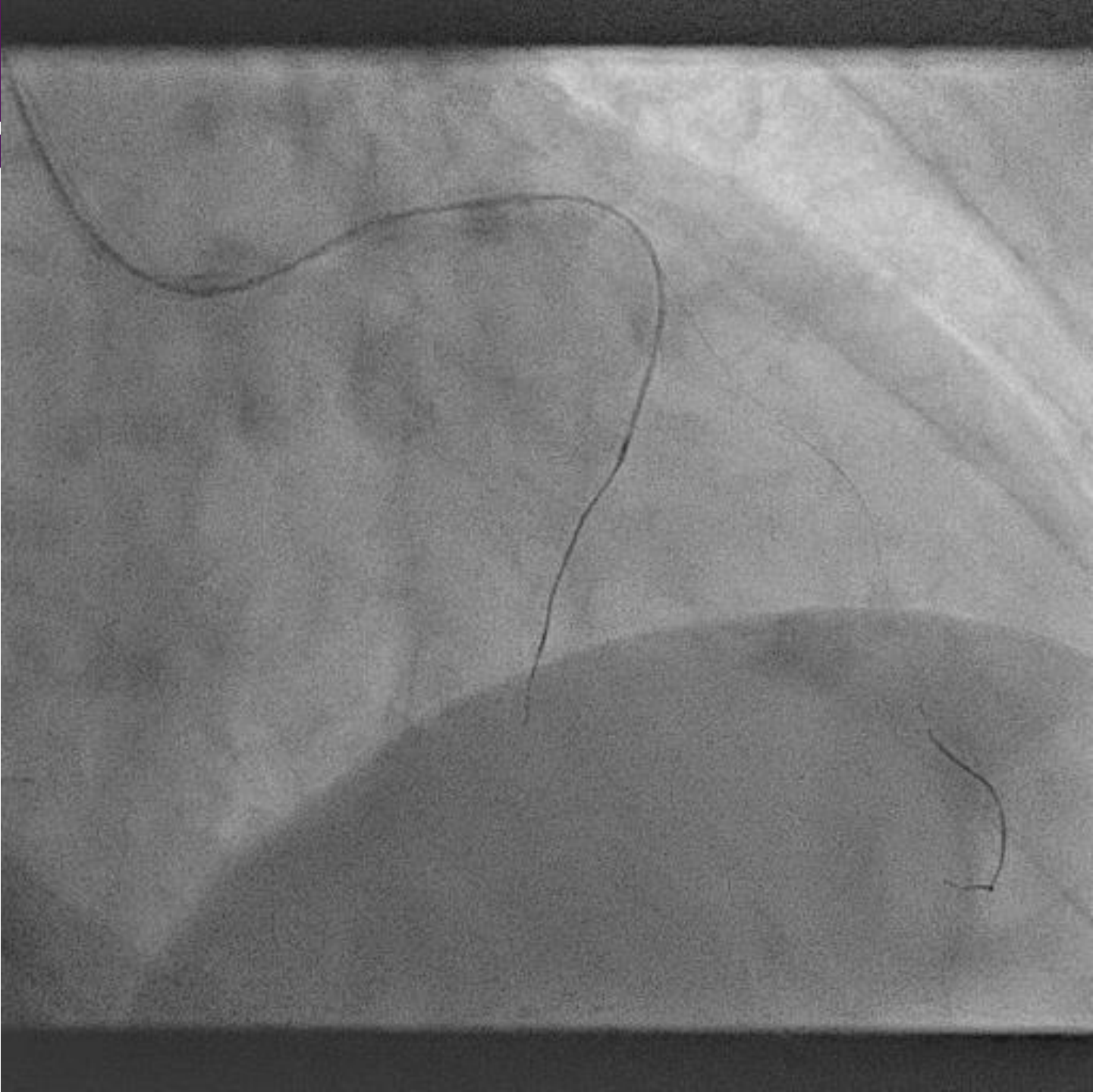
Dr Jack Laffan
Royal Victoria Hospital
Belfast

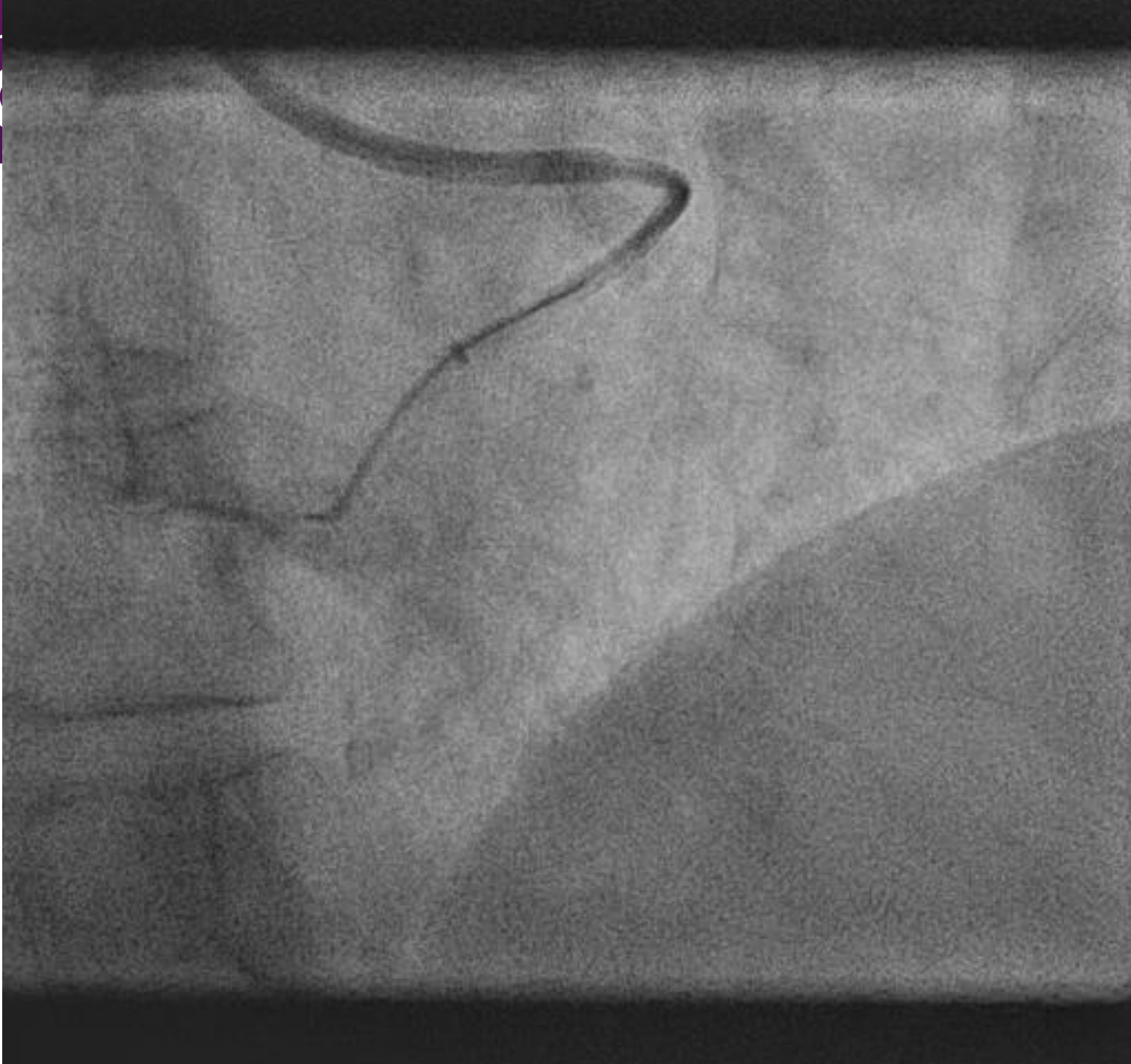- 77yo woman c/o severe angina on minimal effort despite optimal anti-anginals
- Remote history of PCI to mid RCA – Culprit lesion
- Recent failed attempt to revascularise RCA
- Normal LV/ renal function

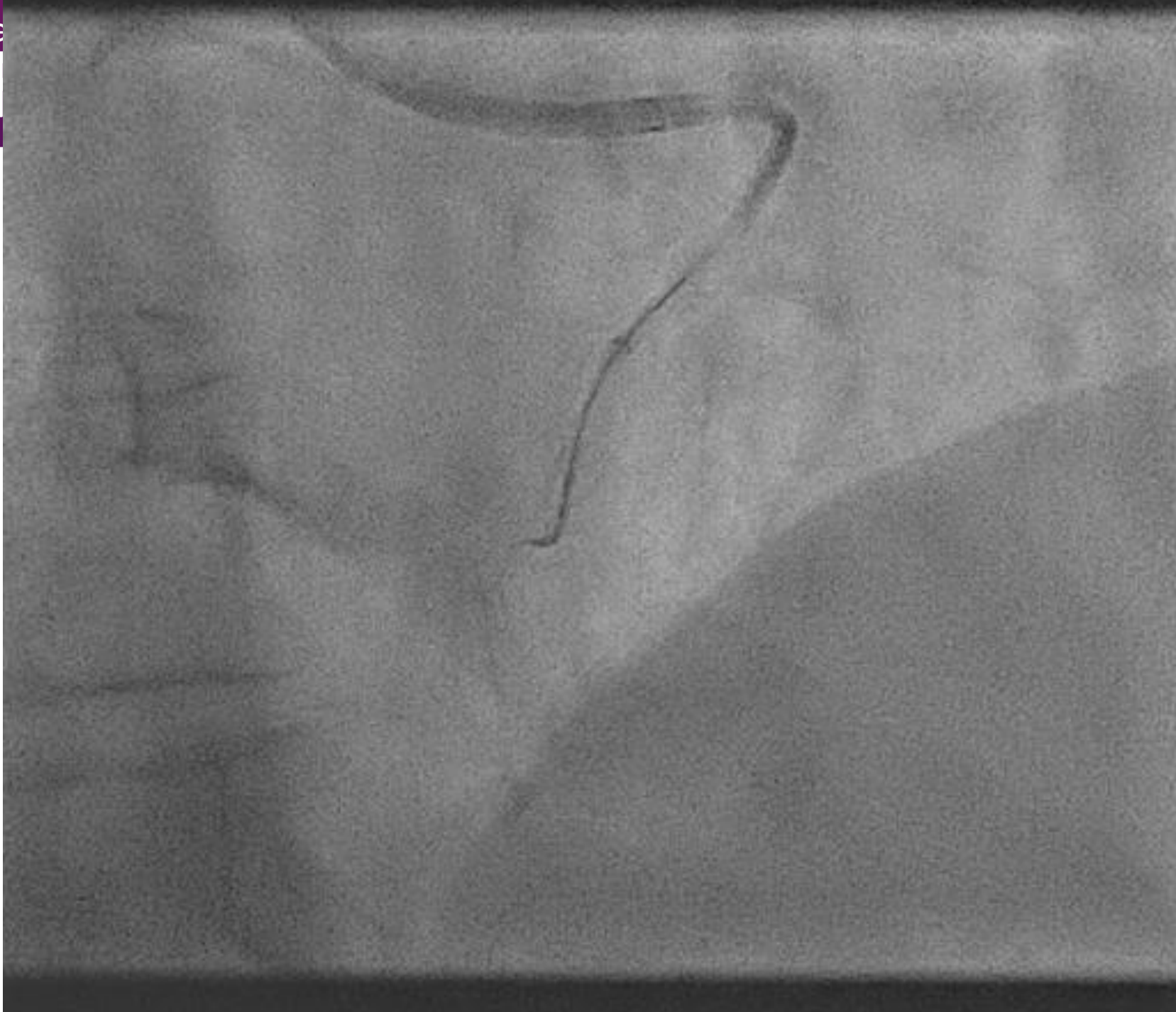


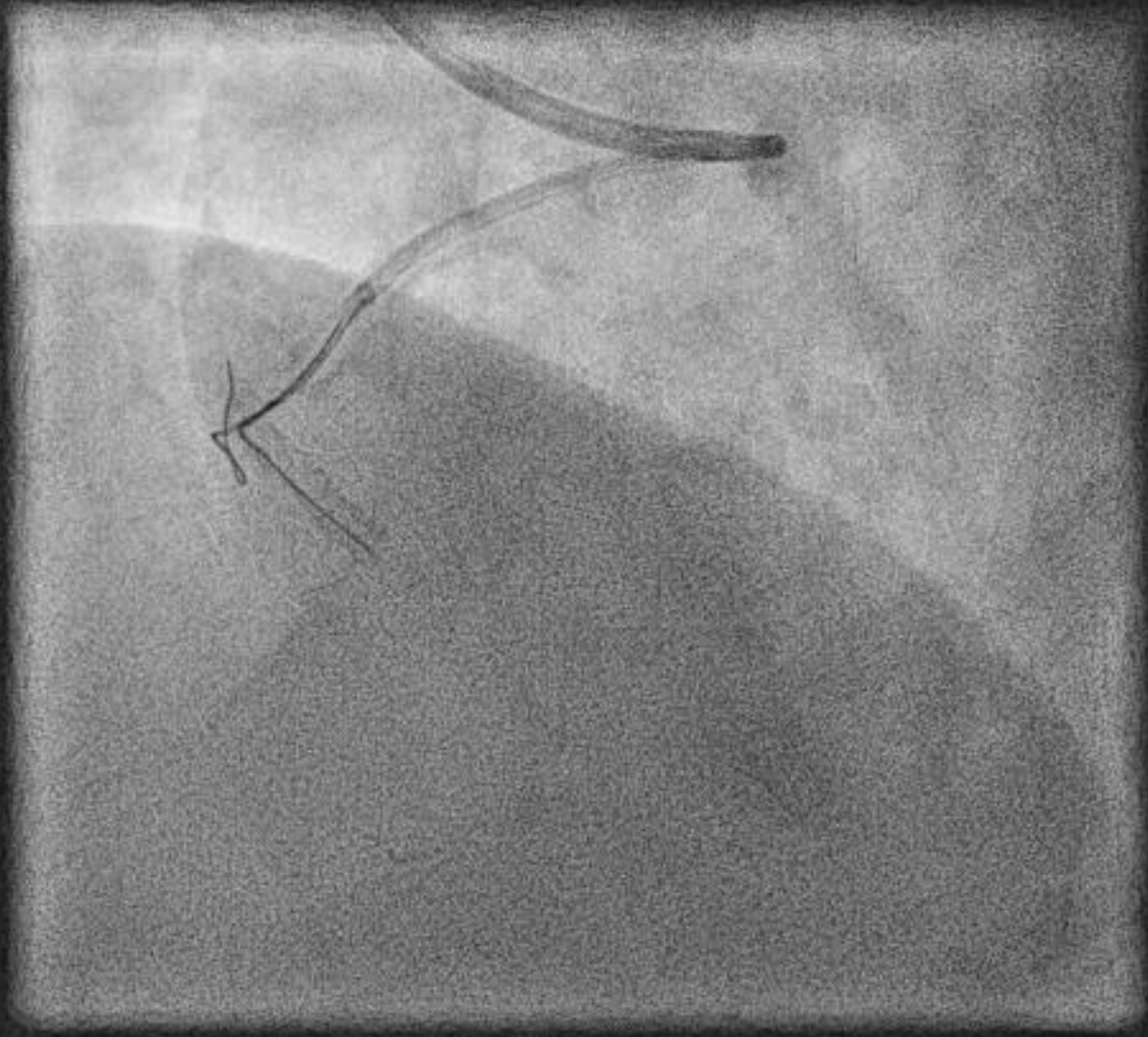




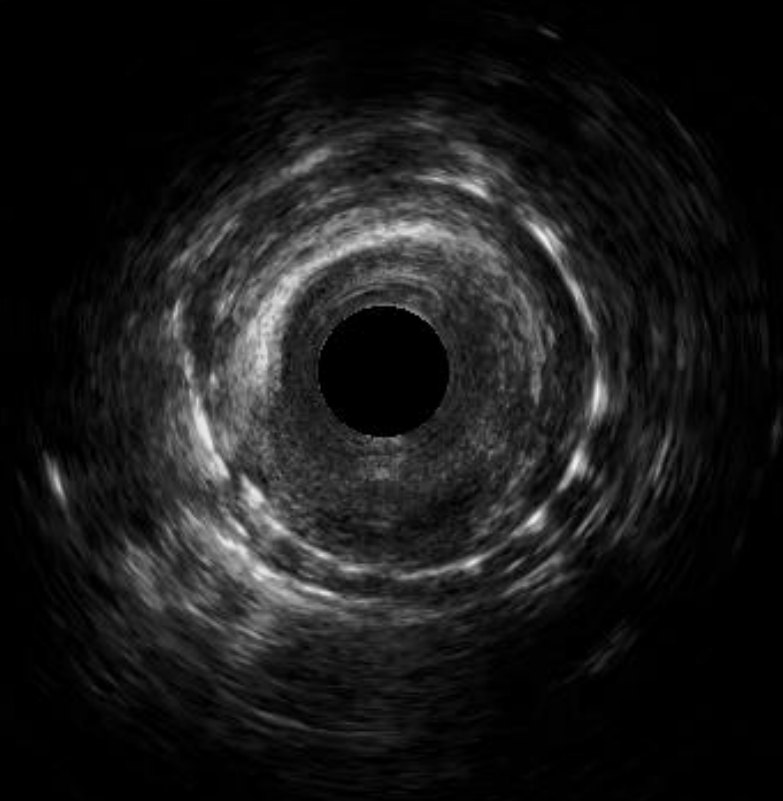








Frame 1142



Frame 1143

