

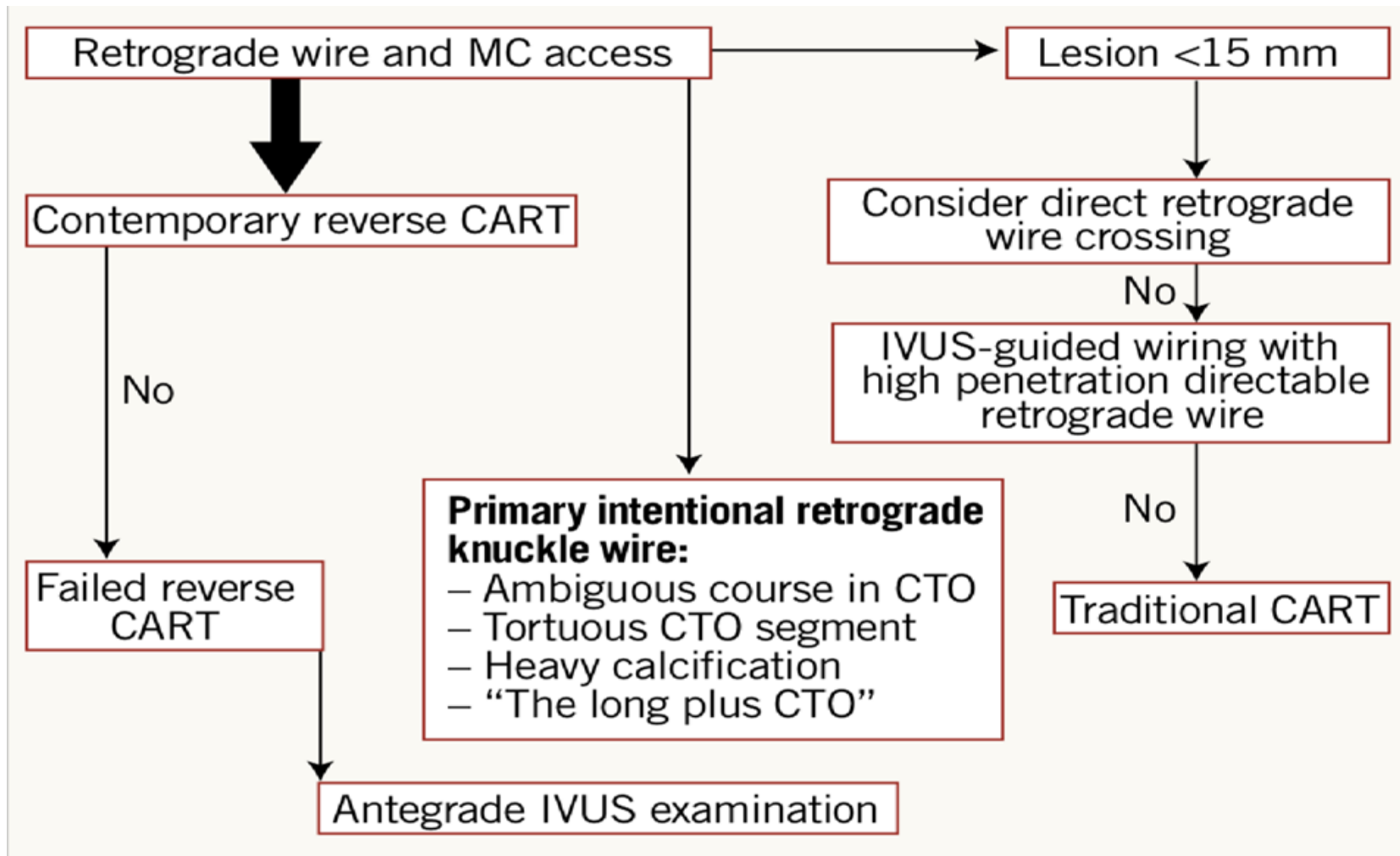


Extension Catheter Facilitated Reverse CART-The Capture Technique

Dr. Rohit Mody

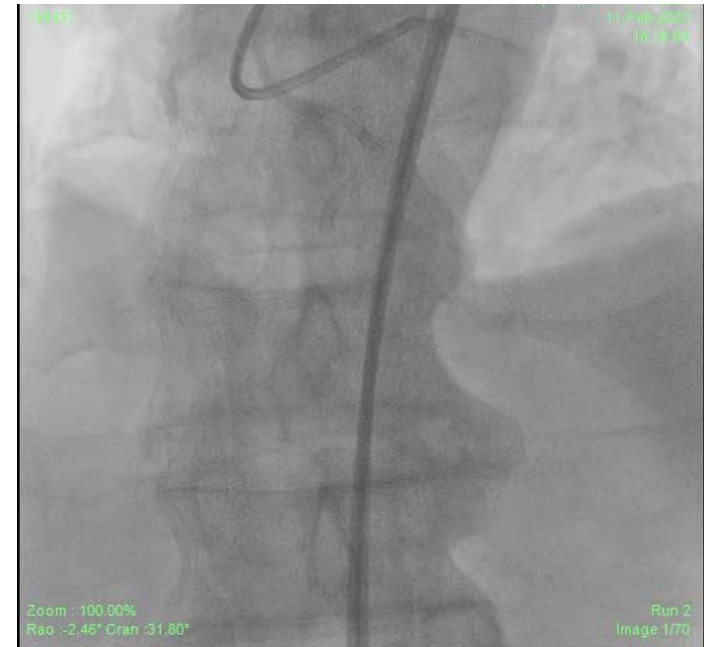
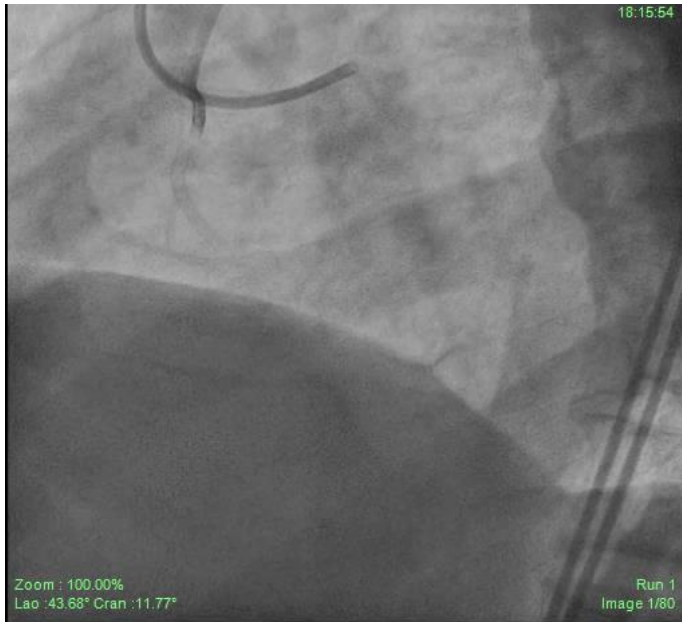
Max Superspeciality Hospital

Bathinda, Punjab

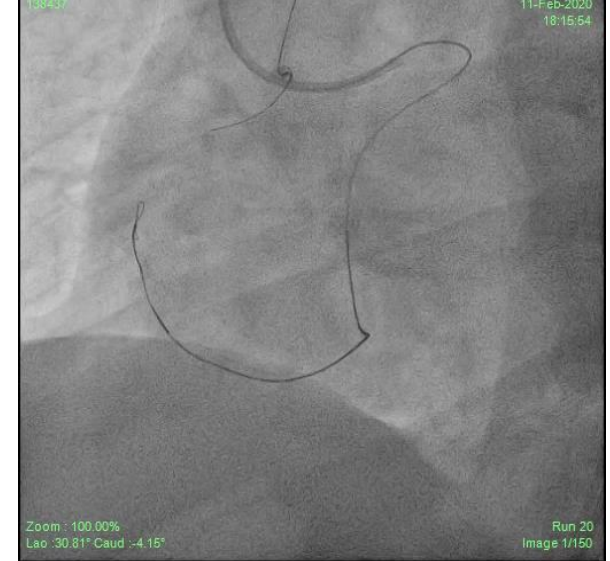
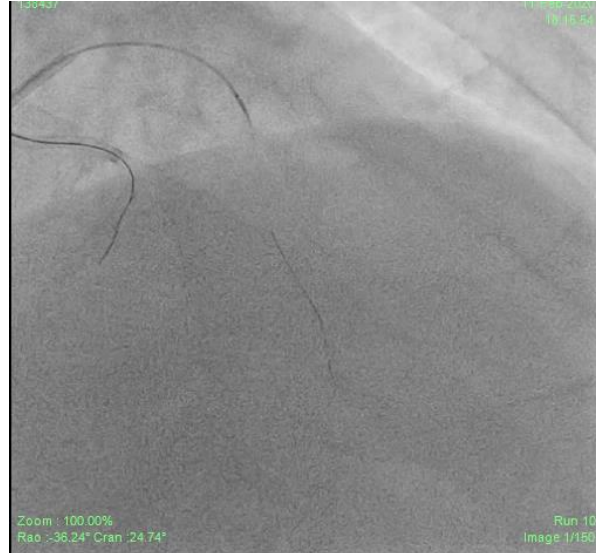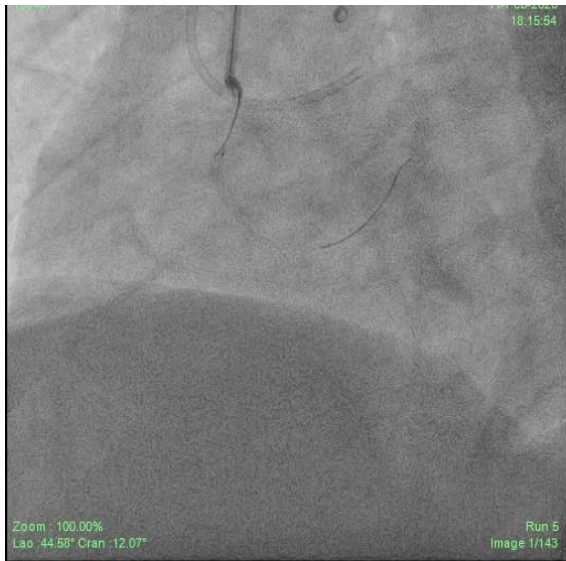


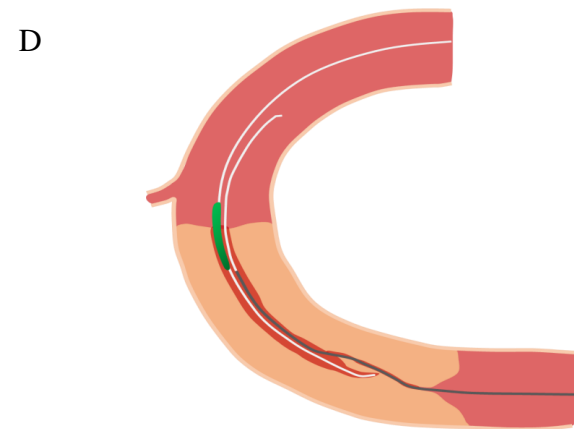
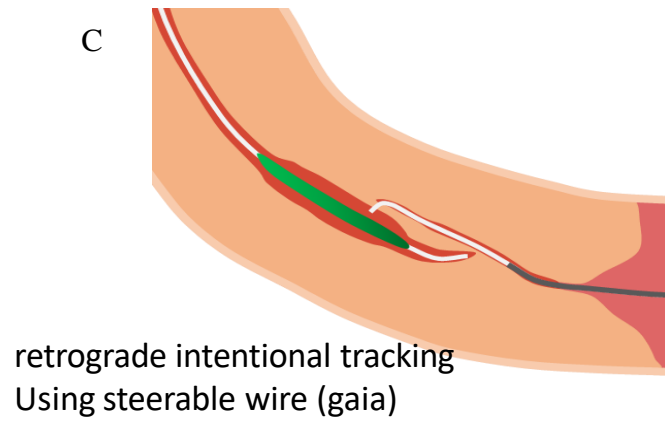
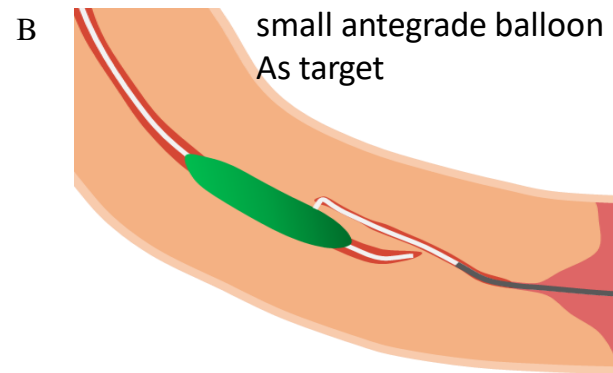
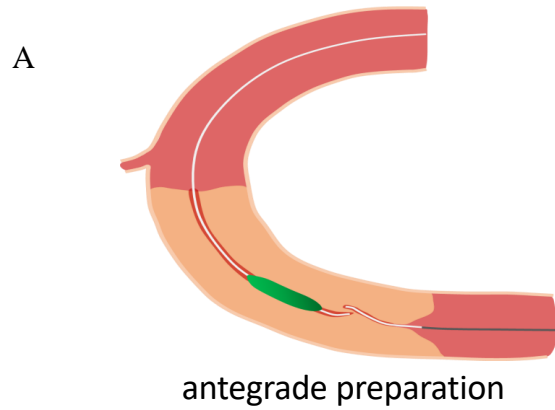
- 65 years old Male
- Known case of CAD
- AOE 3
- Post PTCA + Stent to Abnormal Originating LCX
- Diabetic
- Hypertensive
- Dyslipidemia
- Family History of CAD- Positive
- Still Complains of AOE Class 3

Angiogram Shows normal LAD & Stented Abnormal LCX & RCA CTO 100% long CTO segment distal cap at Bifurcation JCTO score- 2



LAD & Septal crossed with Sion Blue and Corsair catheter advanced from LAD collateral to Mid RCA & Pilot wire extended upto proximal RCA with a knuckle

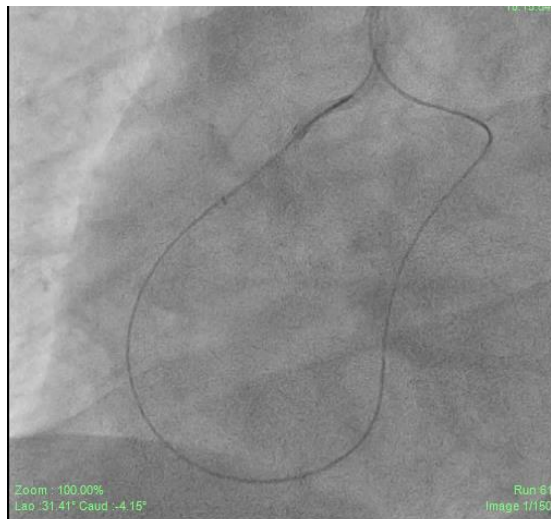
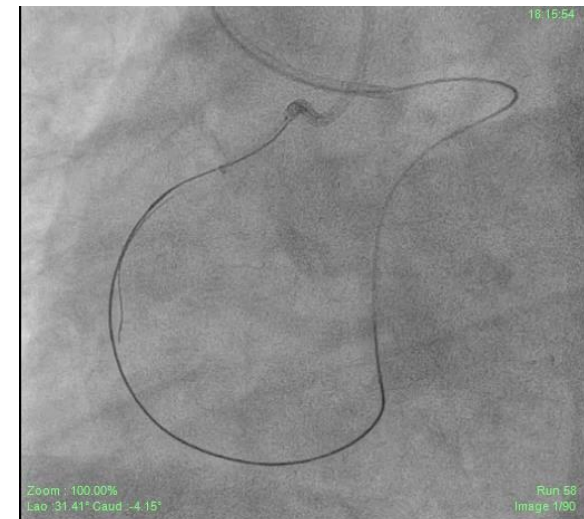
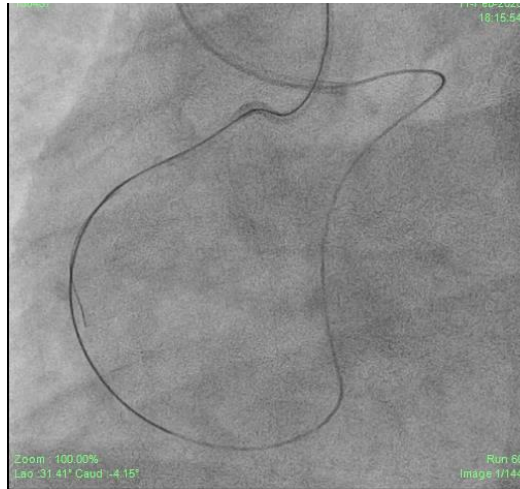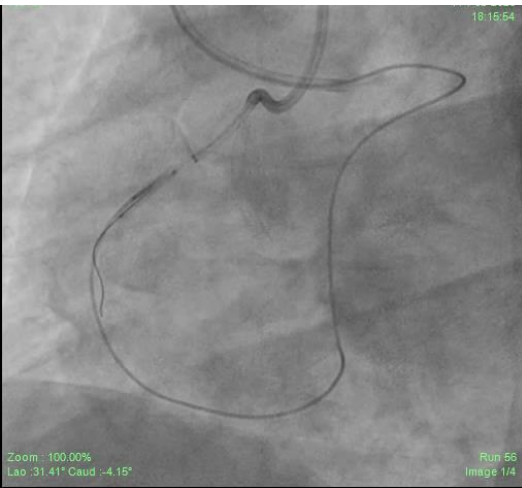




Knuckle wire technique either antegrade or retrograde guidewire creates large spaces resulting in poor retrograde wire control

“Directed” reverse CART is not suitable for:
CTO course ambiguity that cannot be resolved or with severe tortuosity, and heavy calcification.

Guideliner assisted Reverse CART



RG 300cm wire
Exteriorized into RCA
catheter & Corsair taken
Back

Conventional rCART

Matsuno et al.
Eurointervention Jan 2018

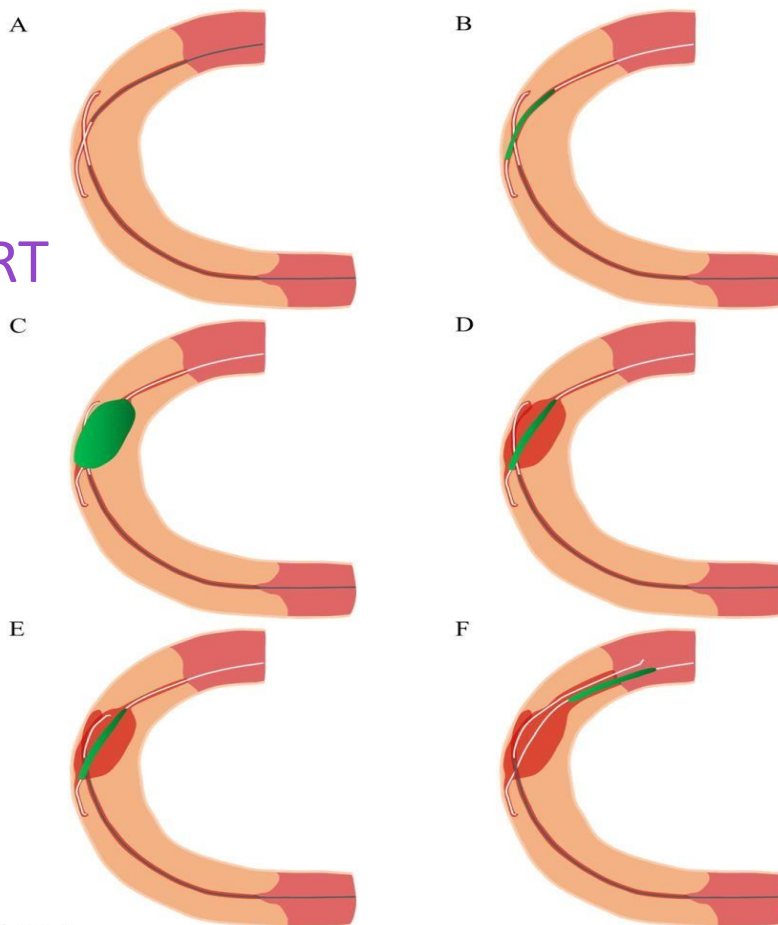
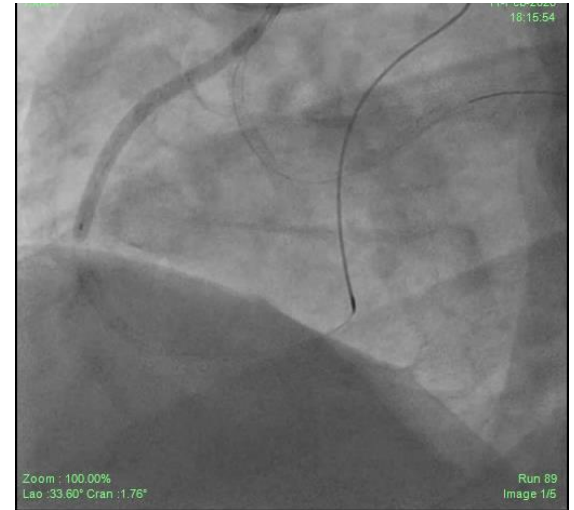
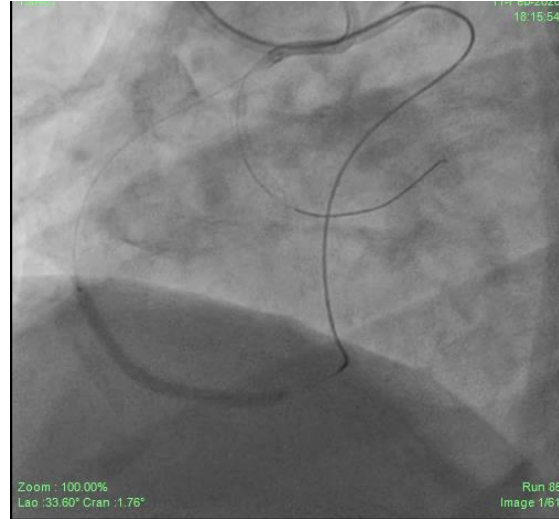
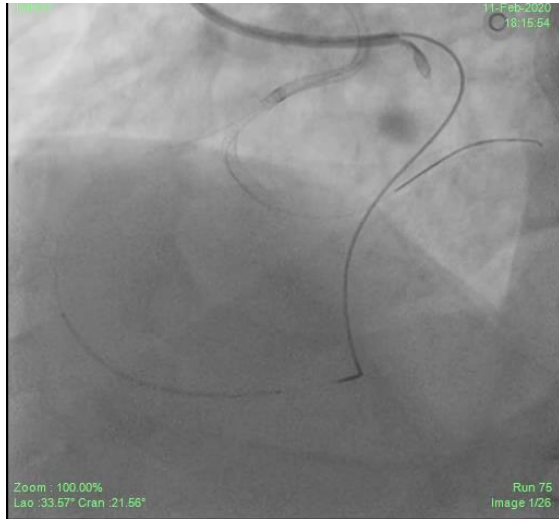


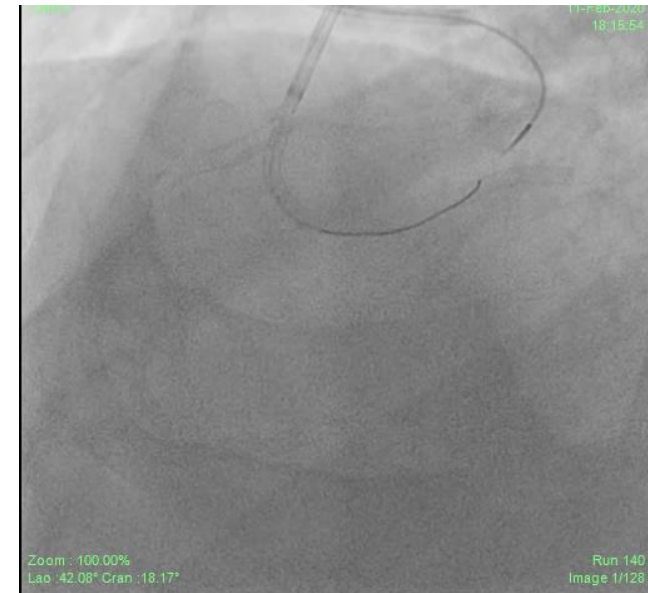
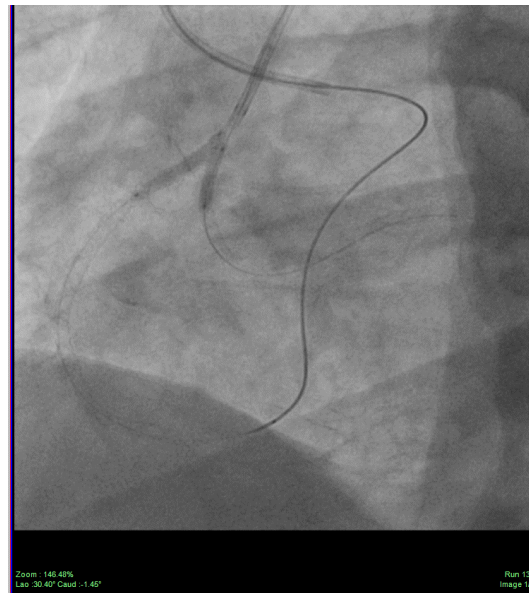
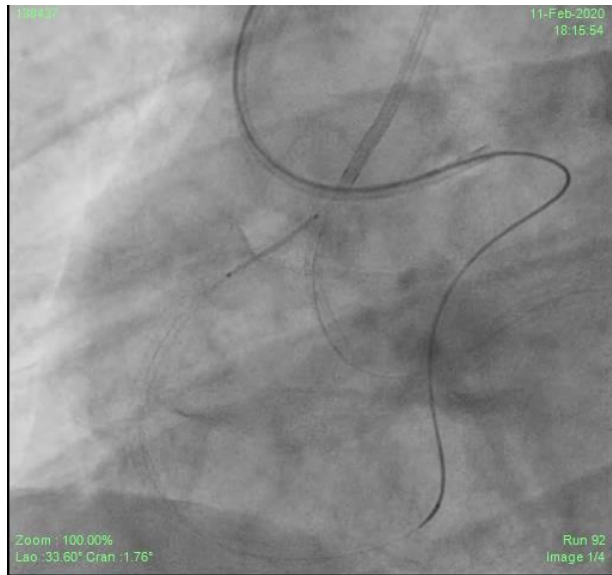
Figure 2.
Illustration of procedural steps of the conventional reverse CART technique.

Distal & Proximal Stents Deployed

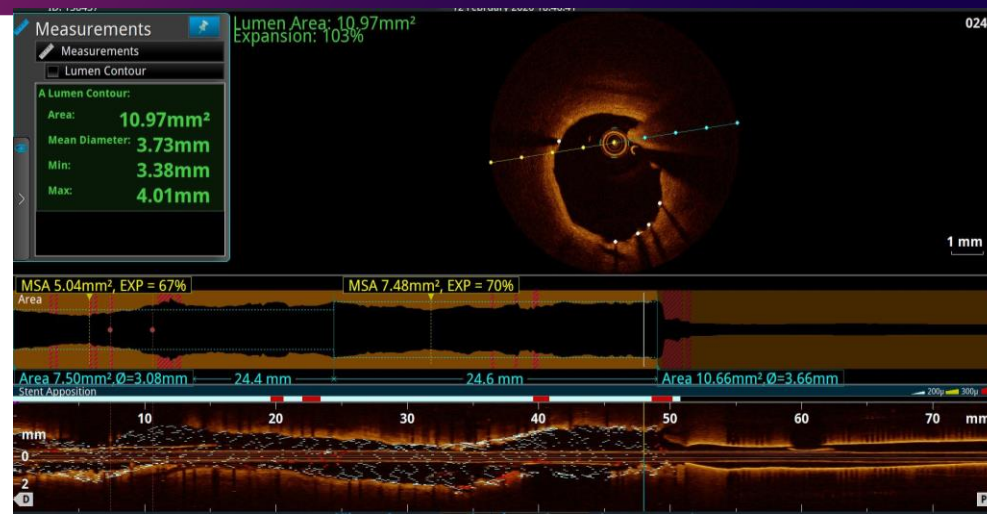


3rd small stent deployed from RCA to LCX, crushing the first Stent

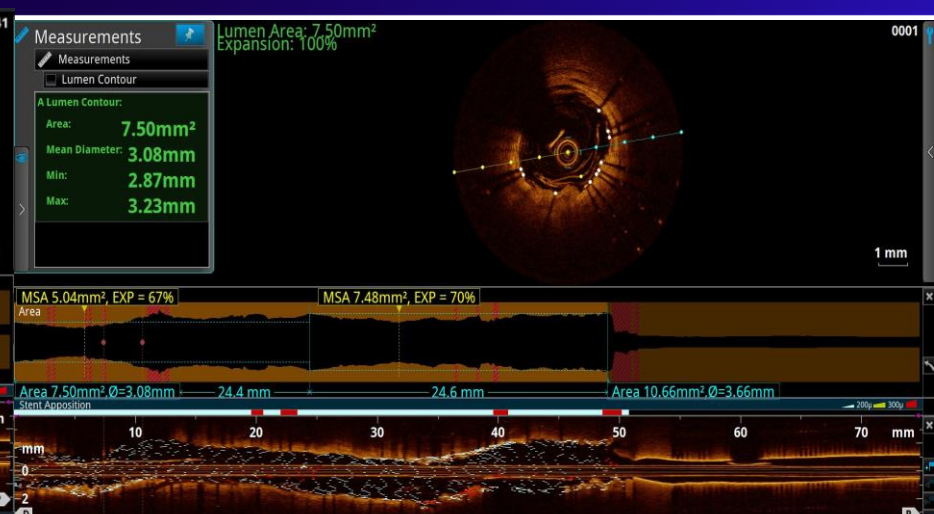
Then LCX Stent Recrossed & Final kissing Done



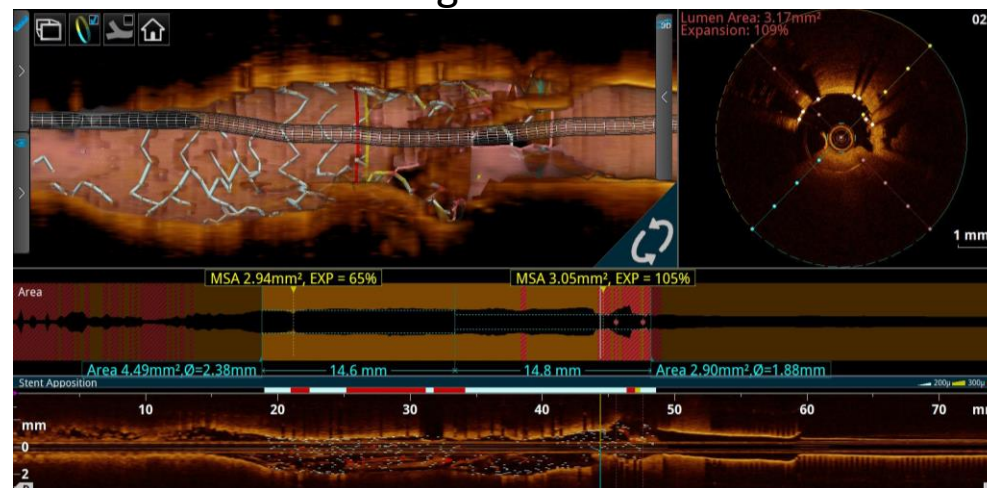
Final Result



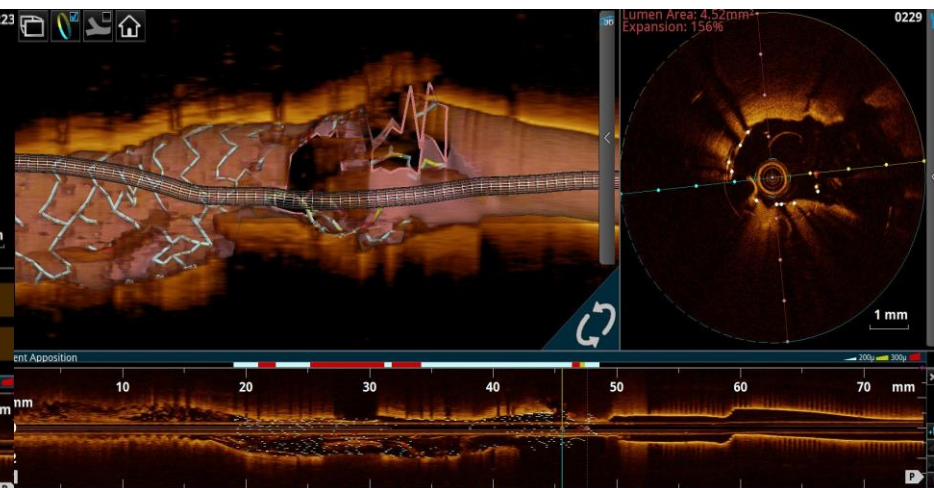
Proximal Edge- RCA-No E.D.



RCA -Distal Edge



LCX: Tissue Prolapse



LCx Bifurcation View: No Pinching

- To Conclude, retrograde PCI using reverse CART should be the first-line option for patients of CTO & abnormally originating artery. Also, during reverse CART in these lesions, Guideliner can help and support antegrade preparation as well as can help in the iteration of reverse CART.