

# Facing a Challenging TV Clip

Christopher U. Meduri, MD MPH

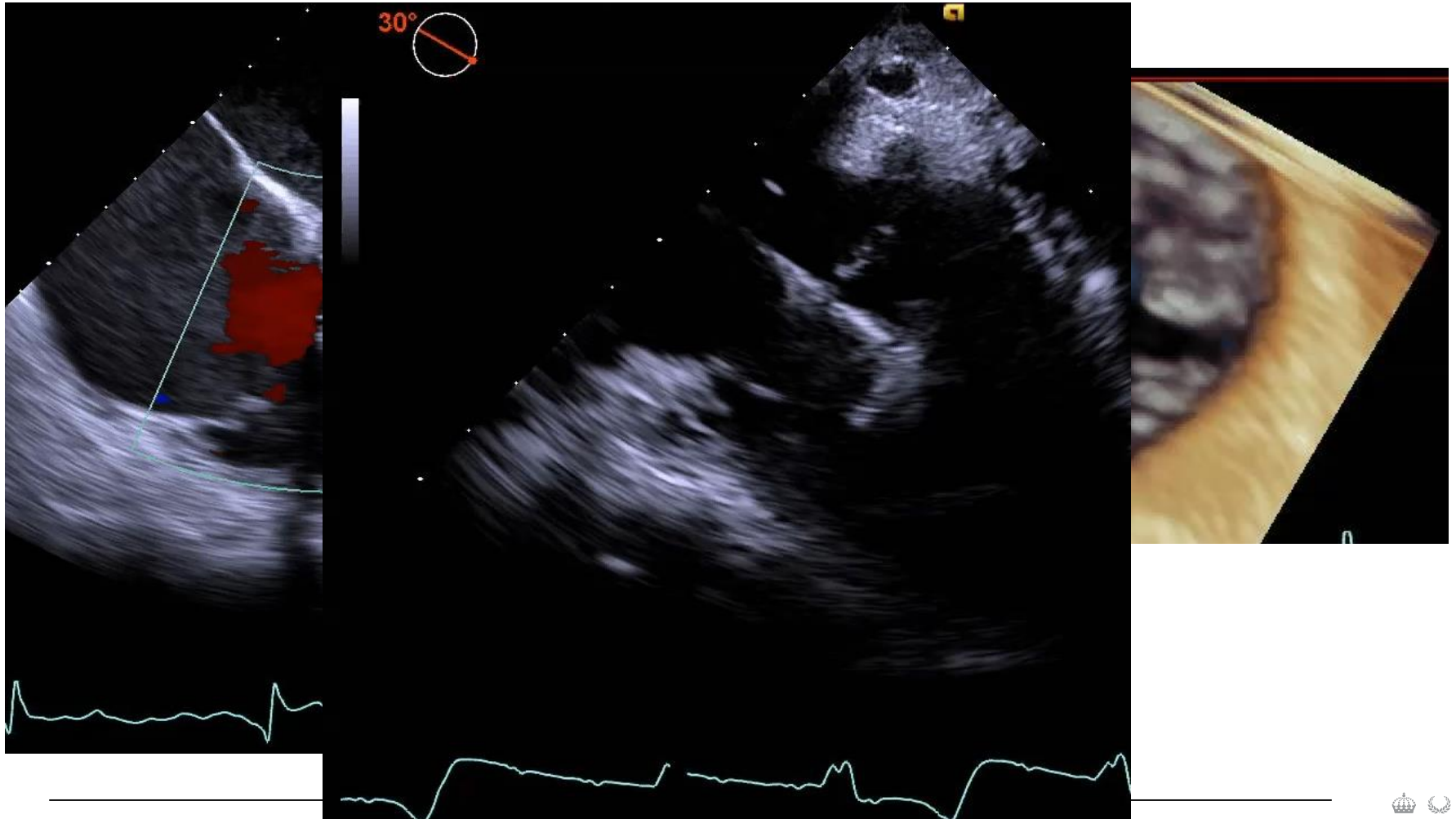
Andreas Rück, MD PhD

# 64 yo F with Severe Tricuspid Regurgitation (5+)

- Prior CABG with long post-op course (patent grafts)
- Lupus with lupus anti-coagulant
- Breast cancer with chest radiation
- Afib
- OSA
- NYHA III despite 80mg Torsemide daily
- PASP 42mmHg
- RV mild dysfunction

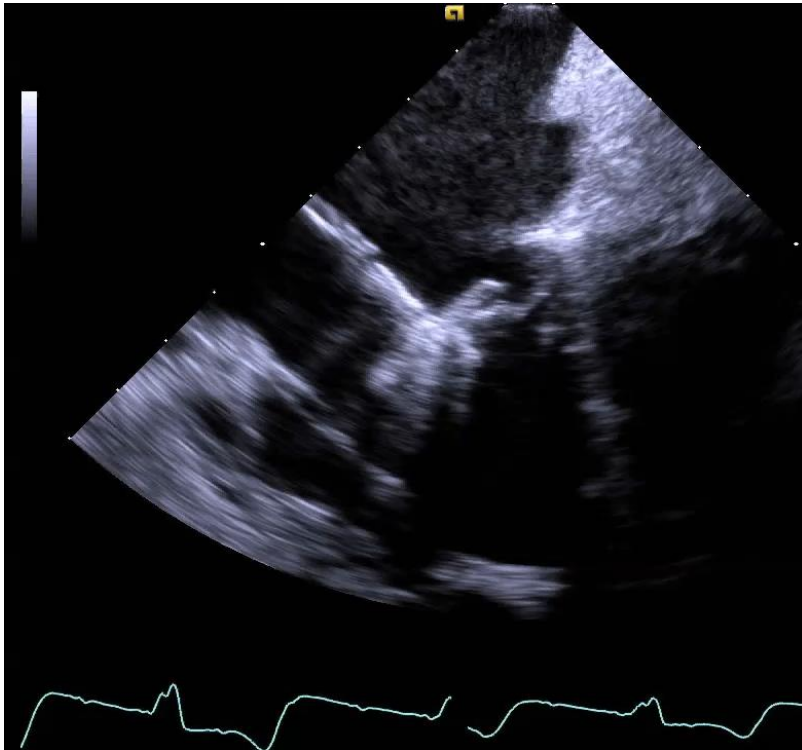
*Torrential TR by 3D PISA EROA: 0.82 (2x severe)*

# Challenging Imaging

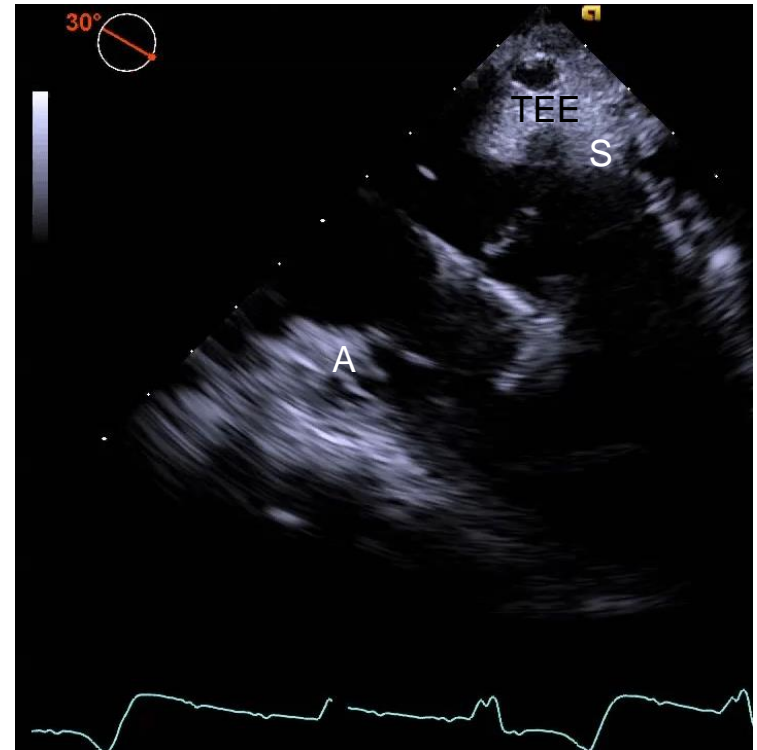


# Comparison of Images on ICE and TEE

ICE

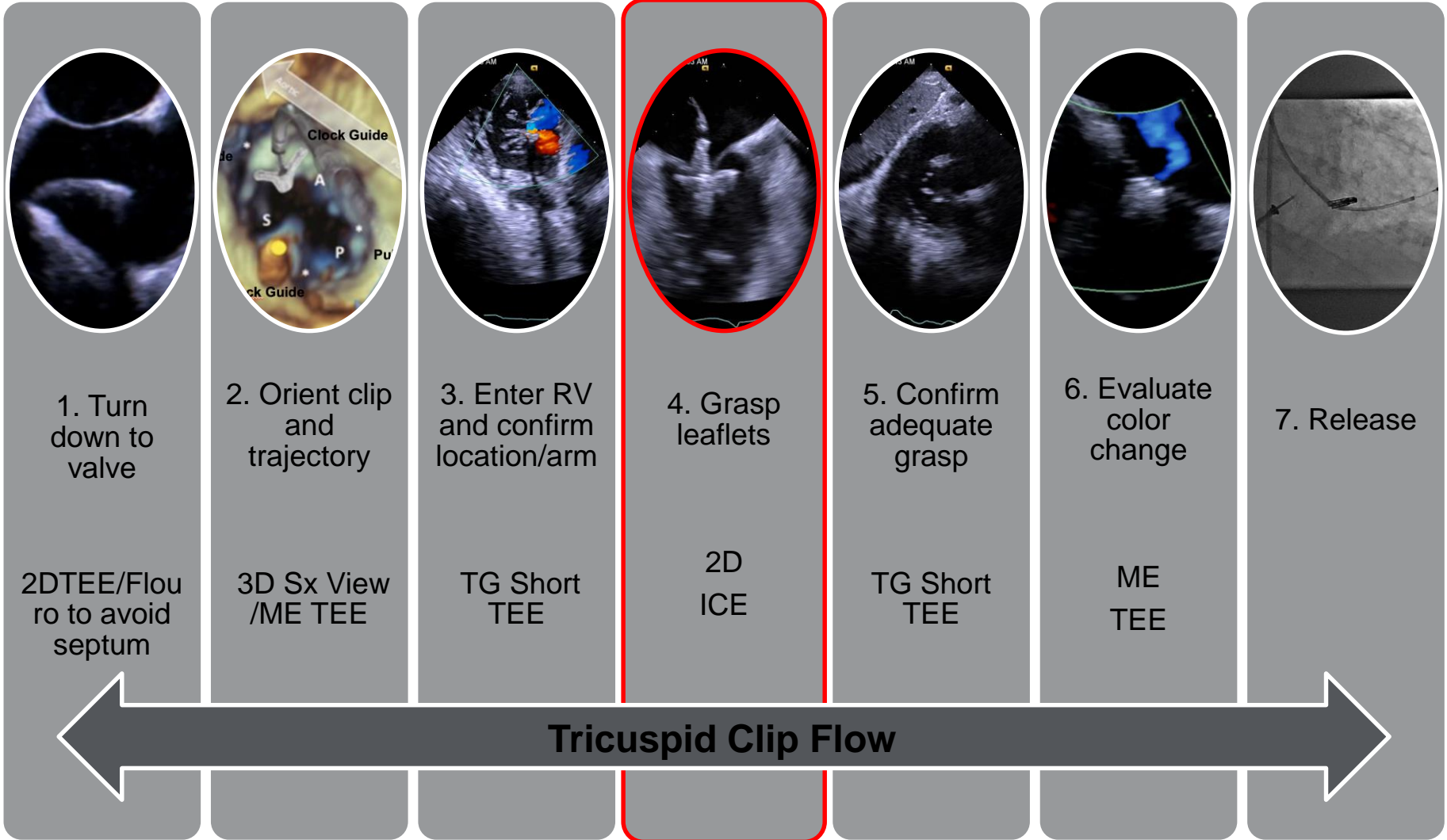


TEE



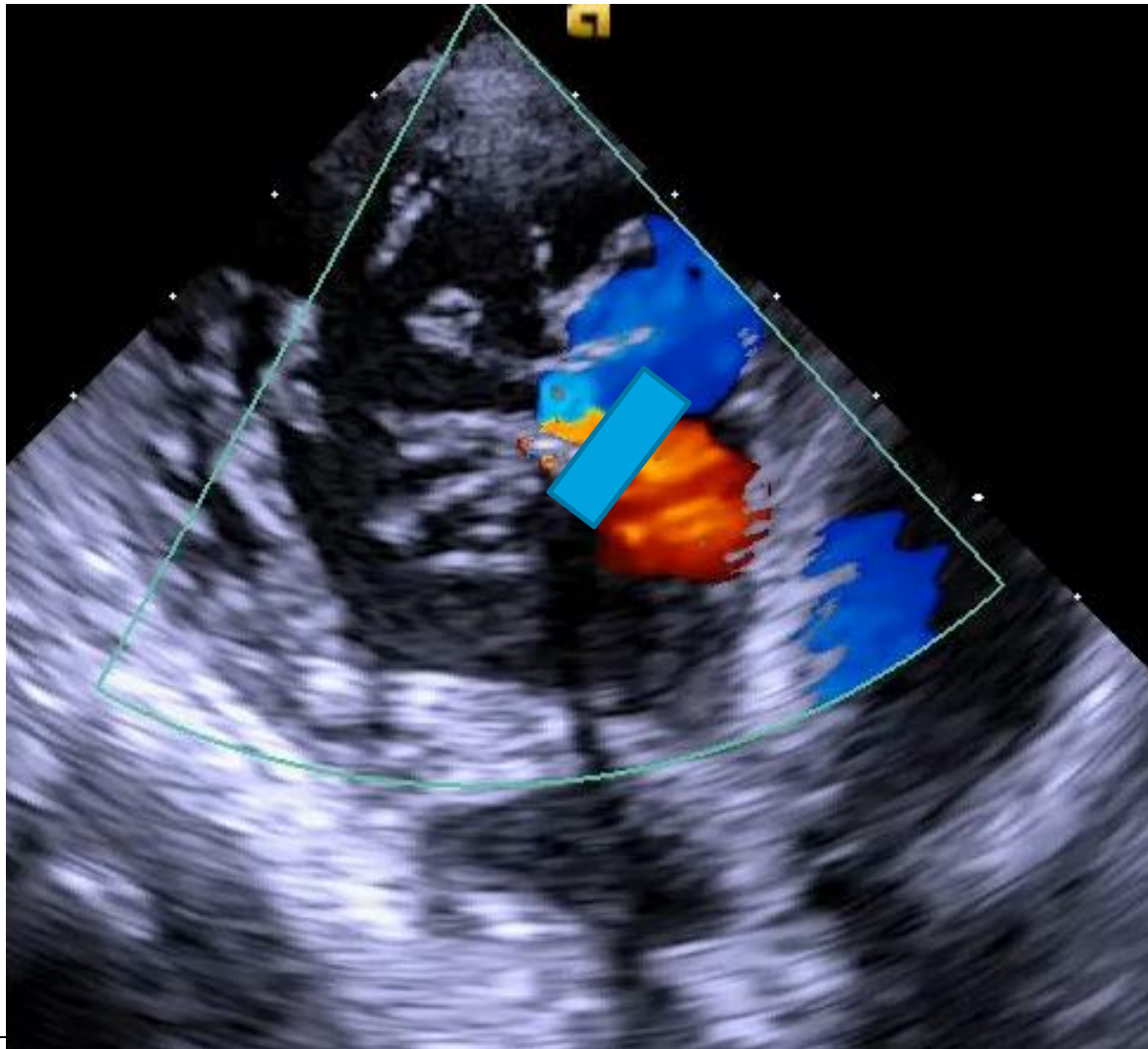
Leaflet Grasping in Modified Home View  
(same as TEE 0° view, not optimal)

# Steps



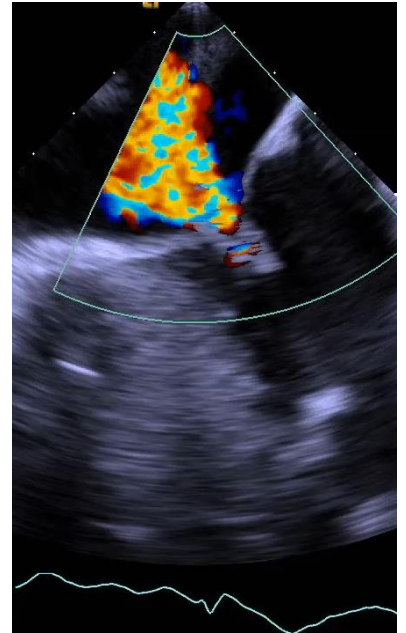
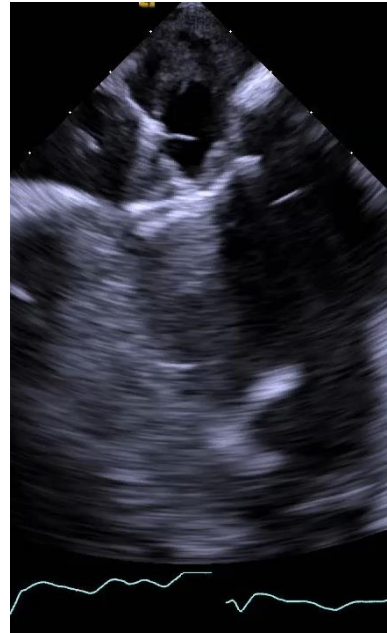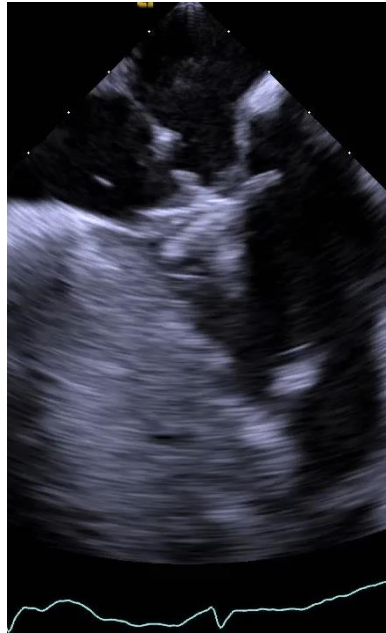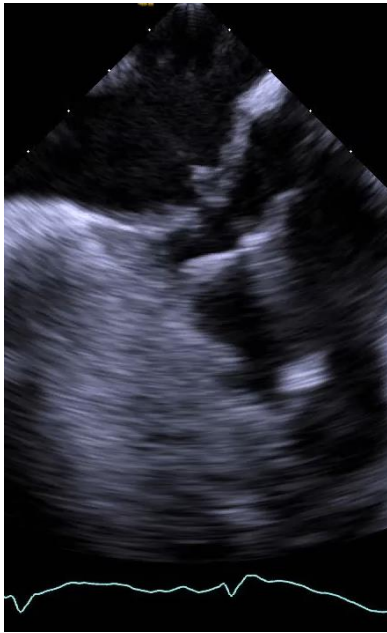ICE only for leaflet grasping

# TG Short to Confirm Orientation

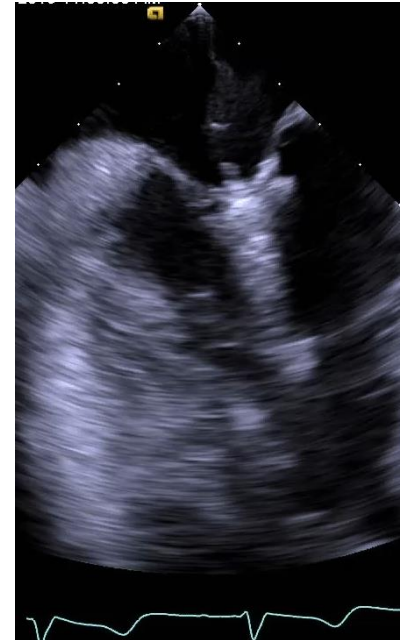
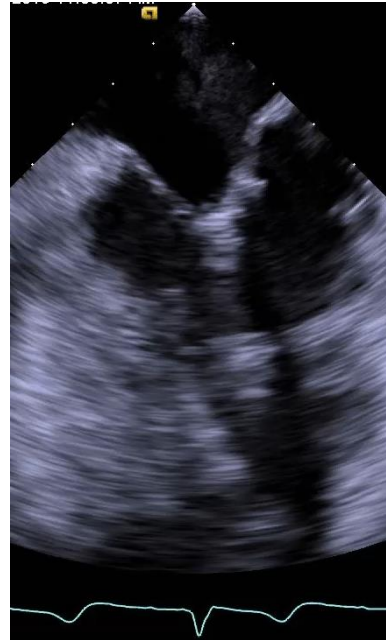
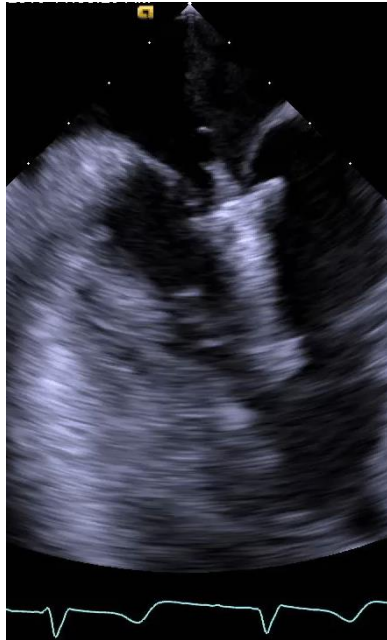
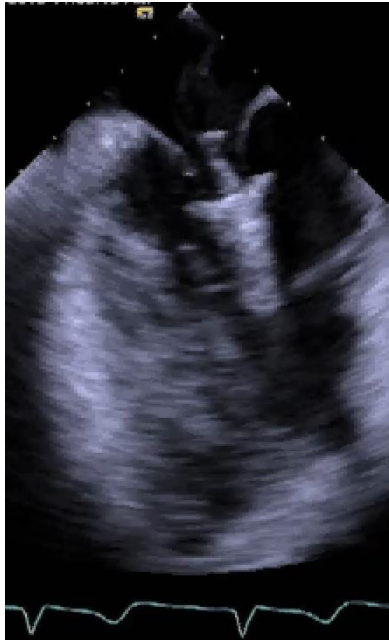
# 1<sup>st</sup> Clip

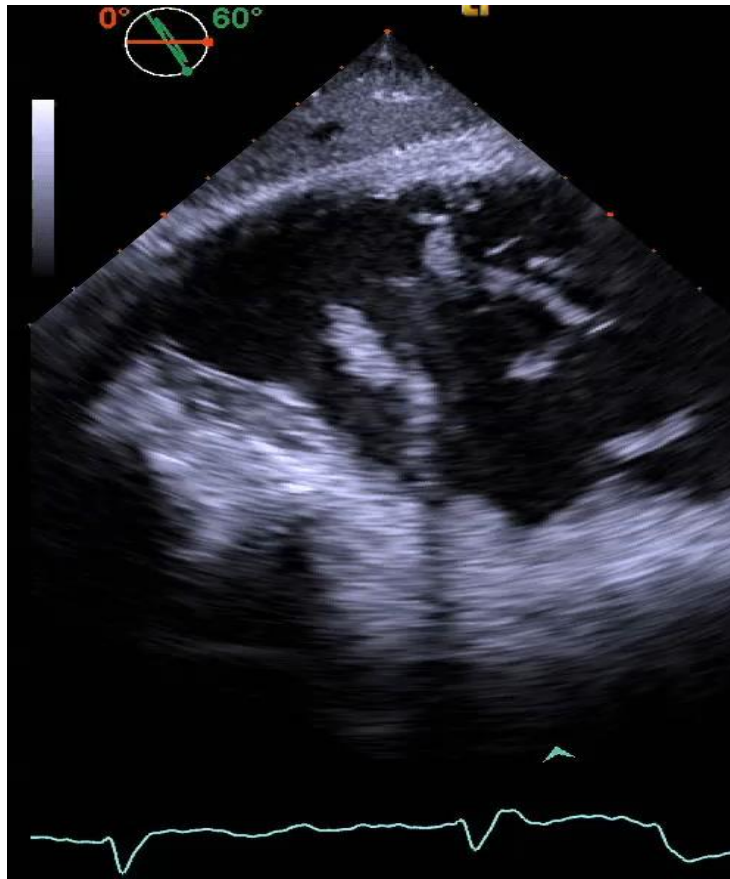


# 3<sup>rd</sup> Clip

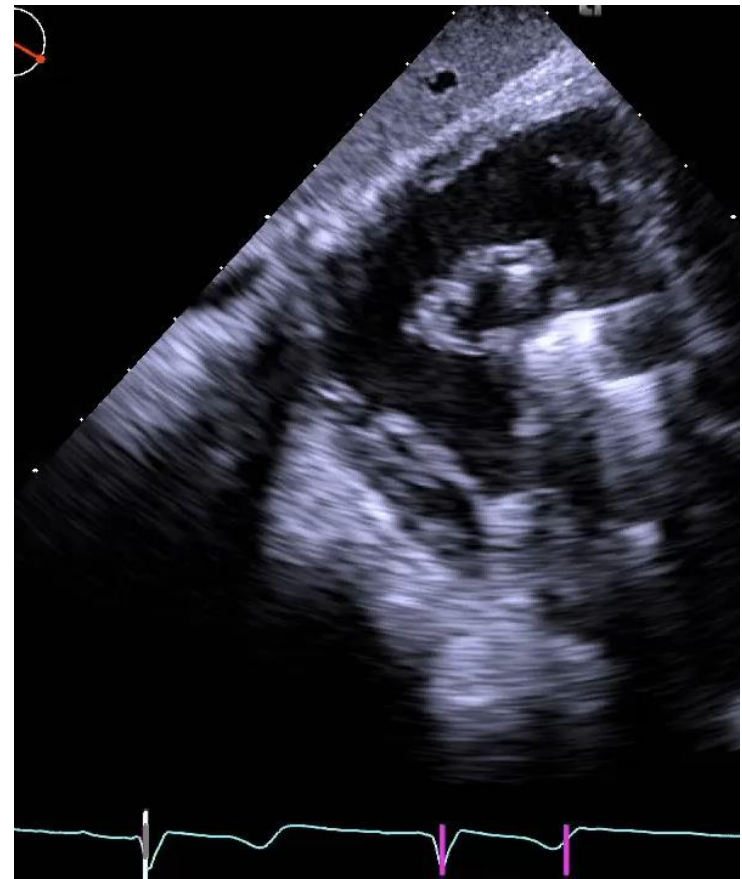



# Confirm Tissue Bridge

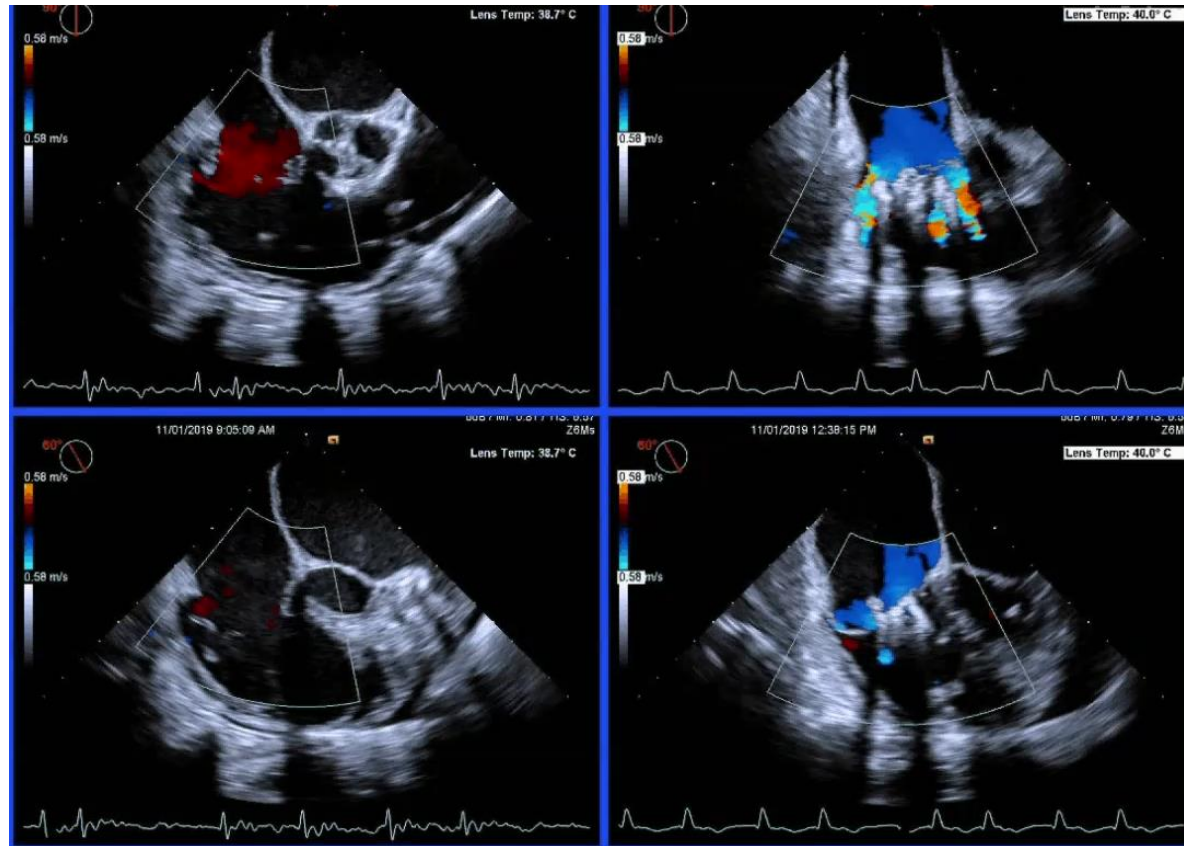


Pre



Post

# Good Result with Aid of ICE



Thank You  
[Chrismeduri@gmail.com](mailto:Chrismeduri@gmail.com)  
@chrismeduri